



PATIENT PRESENTING CLINICAL SIGNS

St. Francis Hutson Right-sided head tilt with history of otitis AD

COMPUTED TOMOGRAPHIC STUDY OF THE HEAD

SPECIES Plain and post contrast studies available for review.

Feline

COMPUTED TOMOGRAPHIC FINDINGS

BREED The right tympanic bulla contains a moderate amount of fluid attenuating material. Moderate thickening of the osseous lining of the right tympanic bulla is seen. There is extensive sclerosis of the right petrous temporal bone involving the cochlea and labyrinthium of the inner ear.

DSH

SEX

An 8 x 3.5mm sized uniformly enhancing elongated soft tissue mass is occupying the horizontal part of the right external auditory meatus and presents stalk like extension to the entrance of the right tympanic bulla. A moderate amount of fluid attenuating material and thickening of the right external auditory meatus are seen as well.

MN

The right medial retropharyngeal lymph node presents mild symmetric enlargement.

AGE COMPUTED TOMOGRAPHIC DIAGNOSIS

- 1 Year
- Chronic righthand sided otitis externa, media, and interna with chronic inflammatory polyp in the horizontal external auditory meatus.
 - Mild right medial retropharyngeal lymph node hyperplasia.

INTERPRETED BY

Nele Eley (Ondreka),
DVM Dr. med. vet.,
DipECVDI

INTERPRETATION OF FINDINGS & FURTHER RECOMMENDATIONS

The CT findings are compatible with chronic righthand sided otitis externa, media, and interna with a chronic inflammatory polyp extending into the horizontal part of the right external auditory meatus. Polyp removal and further otoscopic workup are recommended. At this time, there is no evidence of intracranial extension of the otitis media. The sensitivity of CT to detect early meningeal changes is, however, limited and intracranial extension should be considered a potential differential diagnosis in case of central nervous signs or right facial neuropathy.

HOSPITAL NAME

Mobile Pet Imaging

The lymph node changes are compatible with reactive hyperplasia.

REFERRING VET

Seraydar

INVOICE

56643

DATE

2-8-23



PATIENT

St. Francis Hutson

SPECIES

Feline

BREED

DSH

SEX

MN

AGE

1 Year

INTERPRETED BY

Nele Eley (Ondreka),
DVM Dr. med. vet.,
DipECVDI

HOSPITAL NAME

Mobile Pet Imaging

REFERRING VET

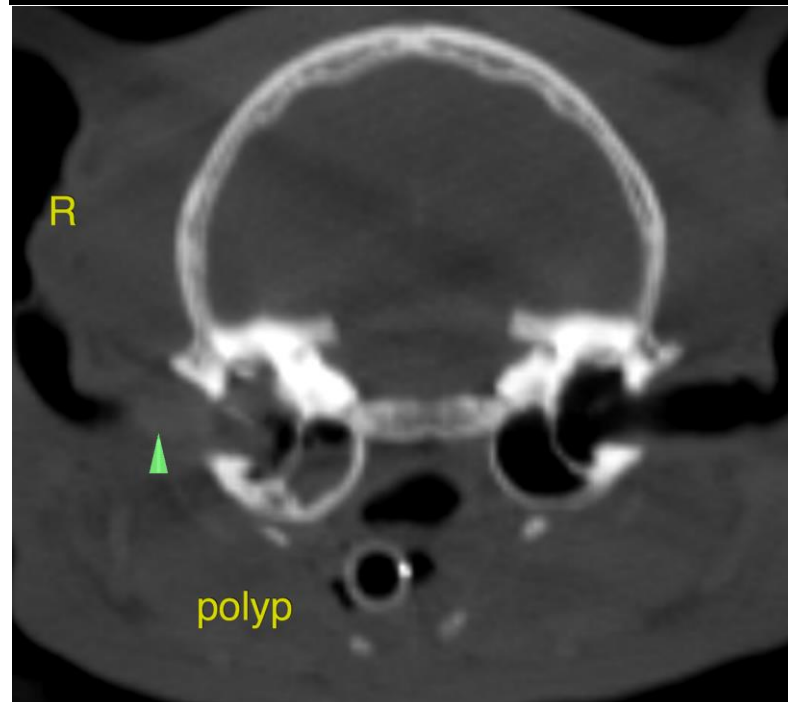
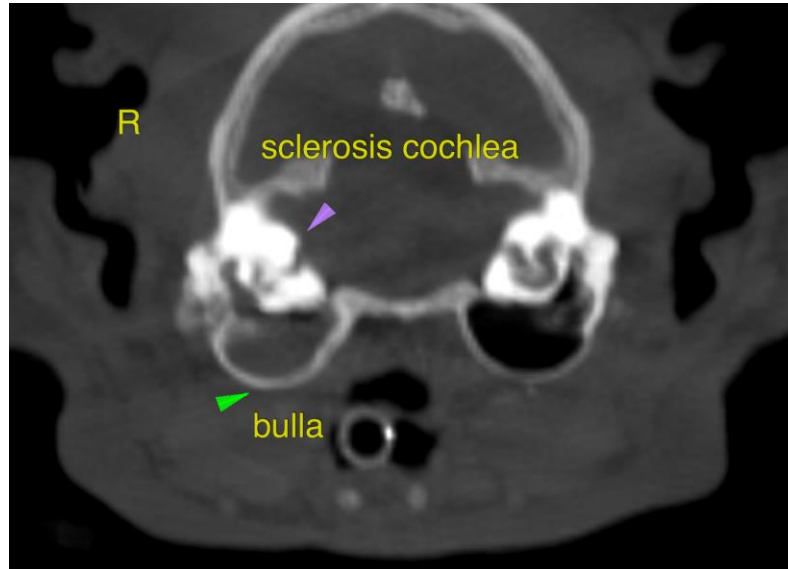
Seraydar

INVOICE

56643

DATE

2-8-23



**PATIENT**

St. Francis Hutson

The information and recommendations provided are based on the images presented by the referring veterinarian. No evaluation can be communicated regarding pathology that was not visible in the image/video clips provided.

SPECIES

Feline

Thank you for this referral. If the clinical or image interpretation does not parallel your findings or if I can be of any further assistance please contact me.

BREED

DSH

Nele Eley (Ondreka), DVM, Dr. med. vet., DipECVDI
European Specialist in Veterinary Diagnostic Imaging, Cert. Radiology,
Senior lecturer University of Giessen/Germany, Veterinary Faculty, Department of Radiology.
Nele.Eley@sonopath.com

SEX

MN

AGE

1 Year

INTERPRETED BY

Nele Eley (Ondreka),
DVM Dr. med. vet.,
DipECVDI

HOSPITAL NAME

Mobile Pet Imaging

REFERRING VET

Seraydar

INVOICE

56643

DATE

2-8-23