



**PATIENT**

Taz Brown

**PRESENTING CLINICAL SIGNS**

4 or 5 days ago Taz was running around and yelped. Ever since then he has been lame on his right hind.

Abnormal PE/Chem/CBC/UA Results: GRADE 3/4 LAMNESS ON RIGHT HIND. PAIN TO PALPATION OF STIFLE SLIGHT CRANIAL DRAWER

**SPECIES**

Canine

**RADIOGRAPHIC STUDY OF THE STIFLES & PELVIS**

Mediolateral and craniocaudal views of both stifles and ventrodorsal and lateral views of the pelvis totaling 8 images available for review.

**BREED**

Labrador Retriever

**RADIOGRAPHIC FINDINGS**

**Pelvis**

Both coxofemoral joints present within age related normal limits.

**SEX**

Male

No lumbosacral junction or pelvic bone abnormality is seen.

**AGE**

9 Years, 7 Months

**Stifles**

Moderate atrophy of the right hind limb musculature is noted.

The right stifle presents moderate articular swelling with mild cranial thrust of the tibia and a mild amount of periarticular osteophytes.

**INTERPRETED BY**

Nele Eley, DVM  
Dr. med. Vet. DipECVDI

Mild articular swelling is seen in the left stifle joint as well. At this time, there is no evidence of osteophytosis or cranial thrust of the tibia.

**HOSPITAL NAME**

Elizabeth Animal  
Hospital

**RADIOGRAPHIC DIAGNOSIS**

- Moderate right stifle osteoarthritis with radiographic signs of cranial cruciate ligament injury.
- Disuse atrophy of the right hind limb musculature.
- Mild articular swelling of the left stifle joint.

**REFERRING VET**

Leon Anderson, DVM

**INTERPRETATION OF THE FINDINGS & FURTHER RECOMMENDATIONS**

The radiographic findings are compatible with cranial cruciate ligament injury of the right stifle with moderate signs of osteoarthritis and disuse atrophy of the right hind limb musculature.

Note the presence of mild articular swelling in the left stifle joint which may indicate presence of early signs of degenerative joint disease, effusion, or synovialitis.

**INVOICE**

50184

**DATE**

2-8-22



**PATIENT**

Taz Brown

**SPECIES**

Canine

**BREED**

Labrador Retriever

**SEX**

Male

**AGE**

9 Years, 7 Months

**INTERPRETED BY**

Nele Eley, DVM  
Dr. med. Vet. DipECVDI

**HOSPITAL NAME**

Elizabeth Animal  
Hospital

**REFERRING VET**

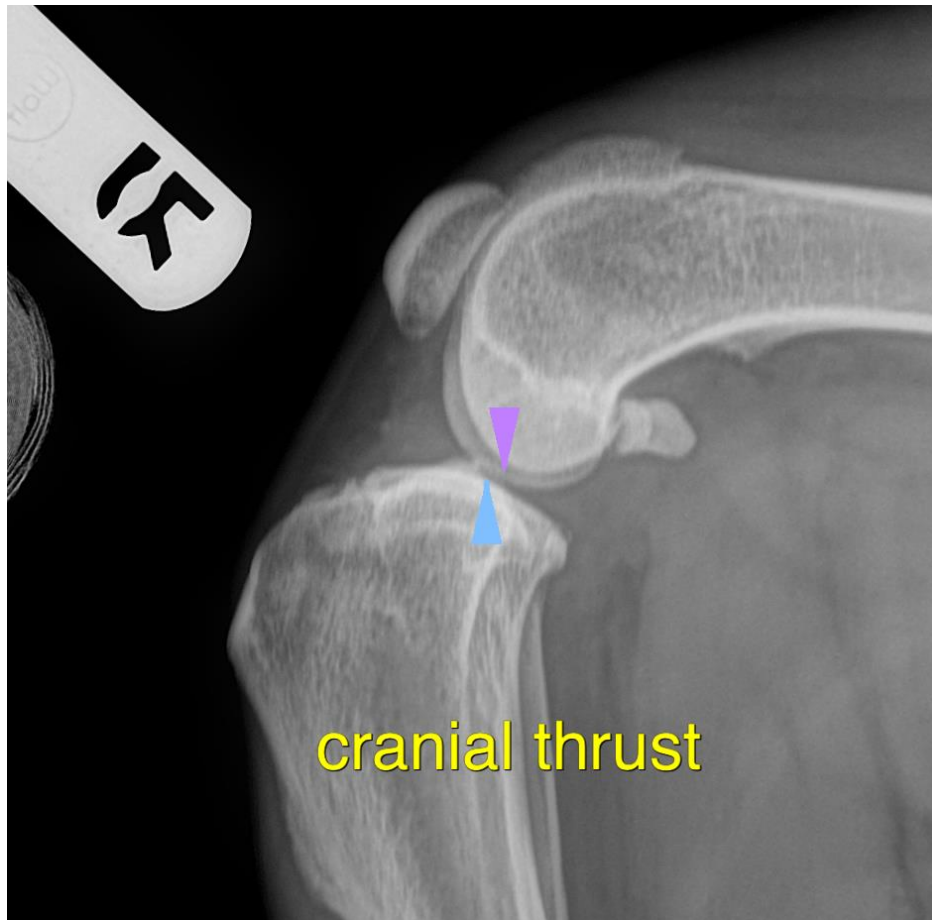
Leon Anderson, DVM

**INVOICE**

50184

**DATE**

2-8-22



The information and recommendations provided are based on the images presented by the referring veterinarian/sonographer. No evaluation can be communicated regarding pathology that was not visible in the image/video clips provided.

Thank you for this referral. If the clinical or image interpretation does not parallel your findings or if I can be of any further assistance please contact me.

**Nele Eley**, DVM, Dr. med. vet., DipECVDI  
European Specialist in Veterinary Diagnostic Imaging, Cert. Radiology,  
Senior lecturer University of Giessen, Germany, Veterinary Faculty, Department of Radiology  
Nele.Eley@sonopath.com