



**PATIENT**

Nala Gharo

**PRESENTING CLINICAL SIGNS**

History of spay in Nov. SQ soft lump noted over spay incision. Cat seems uncomfortable when picked up in that region. Otherwise cat doing fine at home.  
Abnormal PE/Chem/CBC/UA Results: Soft SQ lump over spay incision. All else NSF. No diagnostics performed.

**SPECIES**

Feline

**RADIOGRAPHIC STUDY OF THE CAUDAL ABDOMEN**

Single lateral view of the mid and caudal abdomen available for review.

**BREED**

DSH

**RADIOGRAPHIC FINDINGS**

The abdominal serosal detail is considered within normal limits.

**SEX**

Female Spayed

Mild focal irregularity of the layering of the ventral abdominal musculature is seen in the caudal and ventral abdomen cranial of the urinary bladder.

No evidence of displacement of abdominal viscera is seen radiographically.

**AGE**

8 Months

**RADIOGRAPHIC DIAGNOSIS**

- Focal irregularity of the ventral abdominal musculature after celiotomy.

**INTERPRETATION OF THE FINDINGS & FURTHER RECOMMENDATIONS**

At the time of the radiographic examination, no evidence of displacement of abdominal viscera is seen. Intermittent displacement of abdominal viscera, omentum/mesenteric fat cannot be ruled out and correlation with the clinical palpation is necessary. At the time of the examination, there was no evidence of incarceration.

**INTERPRETED BY**

Nele Eley, DVM  
Dr. med. Vet. DipECVDI

**HOSPITAL NAME**

Northvale Veterinary  
Clinic

**REFERRING VET**

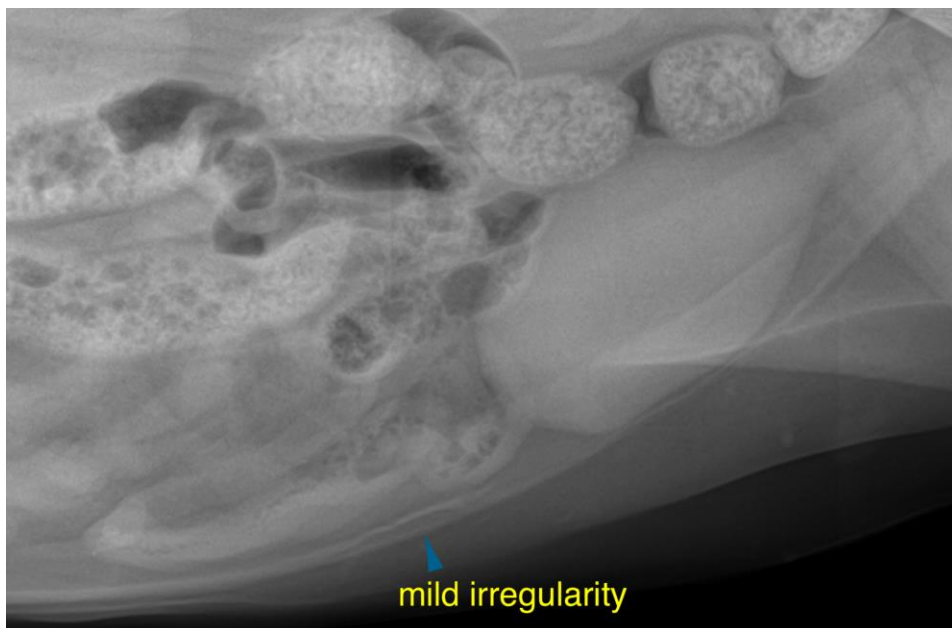
Dr. Stefanie Simon

**INVOICE**

50188

**DATE**

2-8-22





**PATIENT**

Nala Gharo

The information and recommendations provided are based on the images presented by the referring veterinarian/sonographer. No evaluation can be communicated regarding pathology that was not visible in the image/video clips provided.

**SPECIES**

Feline

Thank you for this referral. If the clinical or image interpretation does not parallel your findings or if I can be of any further assistance please contact me.

**BREED**

DSH

**Nele Eley**, DVM, Dr. med. vet., DipECVDI  
European Specialist in Veterinary Diagnostic Imaging, Cert. Radiology,  
Senior lecturer University of Giessen, Germany, Veterinary Faculty, Department of Radiology  
Nele.Eley@sonopath.com

**SEX**

Female Spayed

**AGE**

8 Months

**INTERPRETED BY**

Nele Eley, DVM  
Dr. med. Vet. DipECVDI

**HOSPITAL NAME**

Northvale Veterinary  
Clinic

**REFERRING VET**

Dr. Stefanie Simon

**INVOICE**

50188

**DATE**

2-8-22