



PATIENT

Valor Bakken Paws
Rescue

PRESENTING CLINICAL SIGNS

Chronic URI with on/off heavy mucoid discharge; FIV positive; intermittent response to medications
Abnormal PE/Chem/CBC/UA Results: Upper respiratory stridor; bilateral mucoid dc; slight unkept appearance

SPECIES

Feline

COMPUTED TOMOGRAPHIC STUDY OF THE HEAD

Plain study available for review.

BREED

DSH

COMPUTED TOMOGRAPHIC FINDINGS

Severe turbinate destruction is seen within both nasal cavities. There is a large amount of fluid attenuating material and mucosal swelling noted within both nasal cavities. The right frontal sinus contains a mild amount of fluid attenuating material. The left frontal sinus is completely occupied with fluid attenuating material. The presphenoidal sinuses contain fluid attenuating material.

SEX

MN

Fluid attenuating material is also noted within the tympanic bullae, L>R. Mild thickening of the osseous lining of the left tympanic bulla is seen. The external auditory meatuses present within normal limits.

AGE

9 Months

COMPUTED TOMOGRAPHIC DIAGNOSIS

- Severe chronic bilateral destructive rhinosinusitis.
- Bilateral otitis media, L>R.

INTERPRETED BY

Nele Eley, DVM
Dr. med. Vet. DipECVDI

INTERPRETATION OF THE FINDINGS & FURTHER RECOMMENDATIONS

The CT study reveals bilateral destructive rhinosinusitis. Differential diagnosis includes fungal rhinitis such as aspergillus or cryptococcus and less likely bacterial, viral, or lymphoplasmacytic rhinitis. Further definition requires sampling for culture.

HOSPITAL NAME

State Avenue Vet
Clinic

Note the concurrent presence of bilateral otitis media. Infectious otitis is thought most likely. Further otoscopic workup recommended if not performed already.

REFERRING VET

Dr Raul Casas-Dolz

INVOICE

56623

DATE

2-7-23



PATIENT

Valor Bakken Paws
Rescue

SPECIES

Feline

BREED

DSH

SEX

MN

AGE

9 Months

INTERPRETED BY

Nele Eley, DVM
Dr. med. Vet. DipECVDI

HOSPITAL NAME

State Avenue Vet
Clinic

REFERRING VET

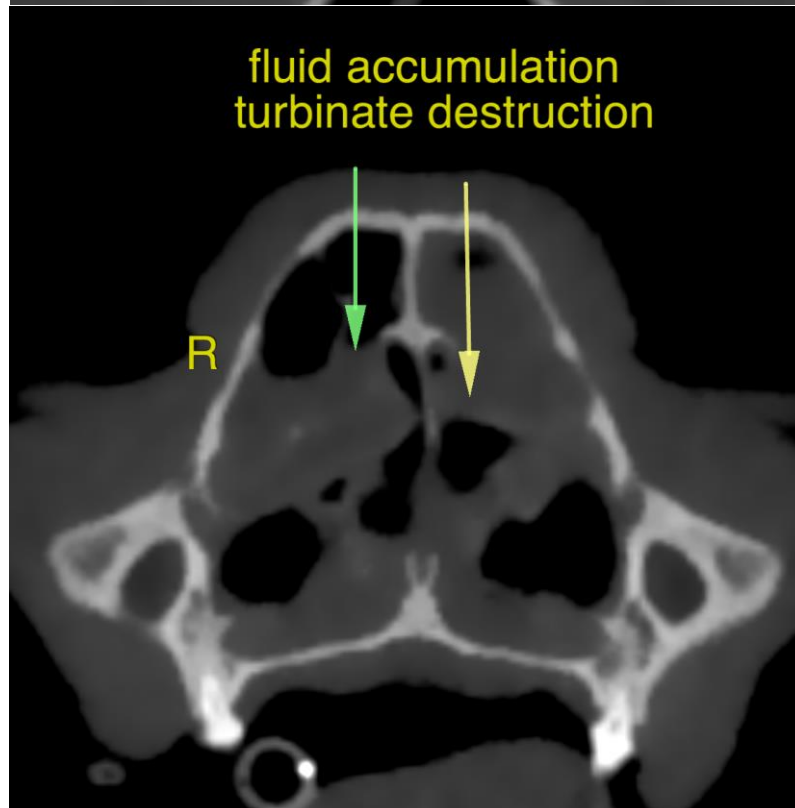
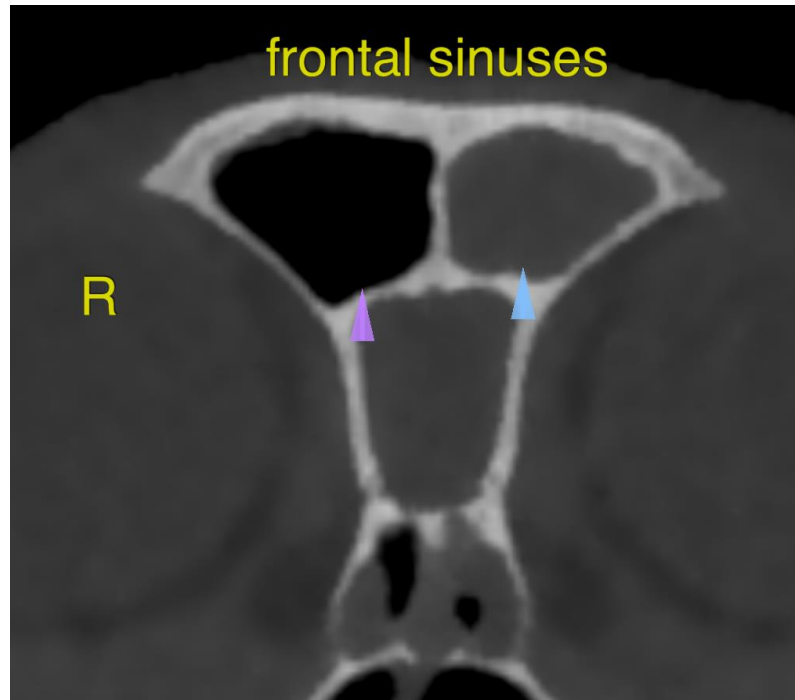
Dr Raul Casas-Dolz

INVOICE

56623

DATE

2-7-23





PATIENT

Valor Bakken Paws
Rescue

SPECIES

Feline

BREED

DSH

SEX

MN

AGE

9 Months

INTERPRETED BY

Nele Eley, DVM
Dr. med. Vet. DipECVDI

HOSPITAL NAME

State Avenue Vet
Clinic

REFERRING VET

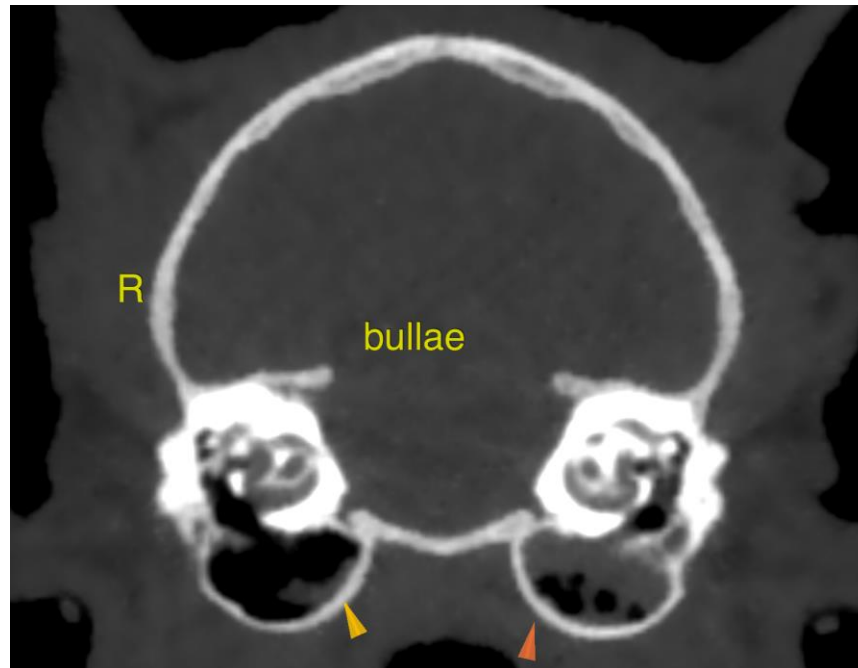
Dr Raul Casas-Dolz

INVOICE

56623

DATE

2-7-23



The information and recommendations provided are based on the images presented by the referring veterinarian/sonographer. No evaluation can be communicated regarding pathology that was not visible in the image/video clips provided.

Thank you for this referral. If the clinical or image interpretation does not parallel your findings or if I can be of any further assistance please contact me.

Nele Eley, DVM, Dr. med. vet., DipECVDI
European Specialist in Veterinary Diagnostic Imaging, Cert. Radiology,
Senior lecturer University of Giessen, Germany, Veterinary Faculty, Department of Radiology
Nele.Eley@sonopath.com