



PATIENT

Lily Panensky

PRESENTING CLINICAL SIGNS

Patient presents for right hind limb limping x 2 weeks after jumping out of car and landing wrong. Abnormal PE/Chem/CBC/UA Results: 11/22 - ALP 526, all else WNL. T4 WNL

SPECIES

Canine

ULTRASONOGRAPHIC FINDINGS

Right Stifle

A large amount of effusion is present within the supra- and infra-patellar recesses of the right stifle joint. Mild periarticular osteophytes are seen. There are moderate synovial proliferations as well as moderate generalized thickening of the synovium. The cranial cruciate ligament is continuous and presents thick, ill-defined, and with multifocal internal heterogeneity. The lateral and medial menisci are in situ, smoothly delineated, and present uniform internal echoarchitectural.

BREED

Labrador Terrier Mix

SEX

FS

Left Stifle

No abnormal effusion is seen within the supra- and infra patellar area. There is no evidence of synovial or capsular thickening or proliferation. The cranial cruciate ligament appears to be continuous and well-delineated, no deviation from normal echoarchitecture is noted. Lateral and medial menisci are within their anticipated positions and align well below the bone surfaces, meniscal surfaces are even and smooth. The echotexture is hypoechoic and uniform. Mild periarticular osteophytes are noted. The infra patellar fat pad present, the expected echo architecture.

AGE

10 Years, 11 Months

INTERPRETED BY

Nele Eley, DVM
Dr. med. Vet. DipECVDI

ULTRASONOGRAPHIC DIAGNOSIS

- Right stifle arthropathy with mild osteoarthritis, moderate synovialitis, and effusion, and evidence of cruciate ligament pathology.

HOSPITAL NAME

Northvale Veterinary
Clinic

INTERPRETATION OF THE FINDINGS & FURTHER RECOMMENDATIONS

The ultrasonographic findings of the right stifle suggest partial rupture of the cranial cruciate ligament, which is concurred by synovialitis, effusion, and mild osteoarthritic changes. No evidence of meniscopathy was detected at the time of the examination.

REFERRING VET

Dr. Stefanie Simon

INVOICE

56614

DATE

2-7-23



PATIENT

Lily Panensky

SPECIES

Canine

BREED

Labrador Terrier Mix

SEX

FS

AGE

10 Years, 11 Months

INTERPRETED BY

Nele Eley, DVM
Dr. med. Vet. DipECVDI

HOSPITAL NAME

Northvale Veterinary
Clinic

REFERRING VET

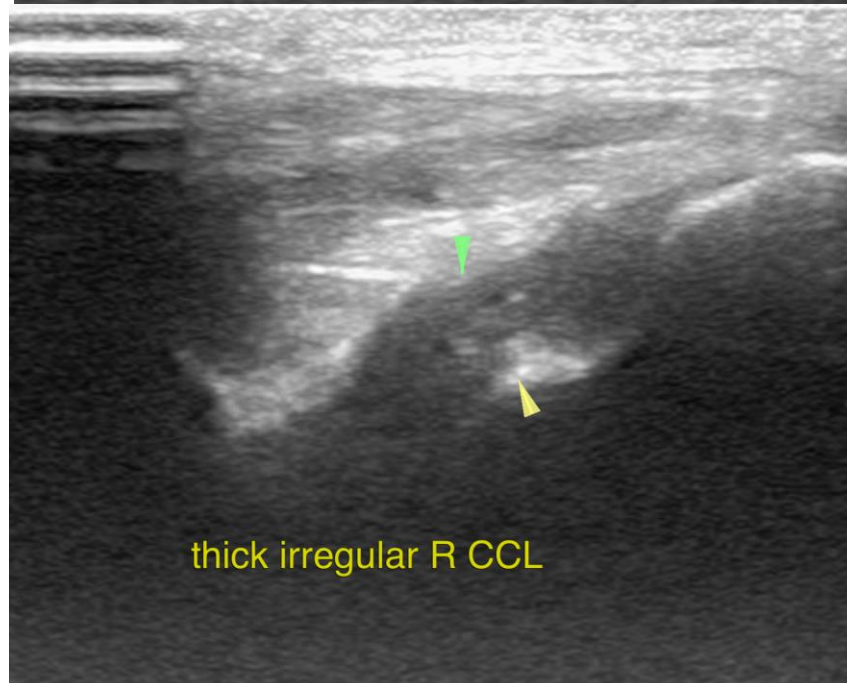
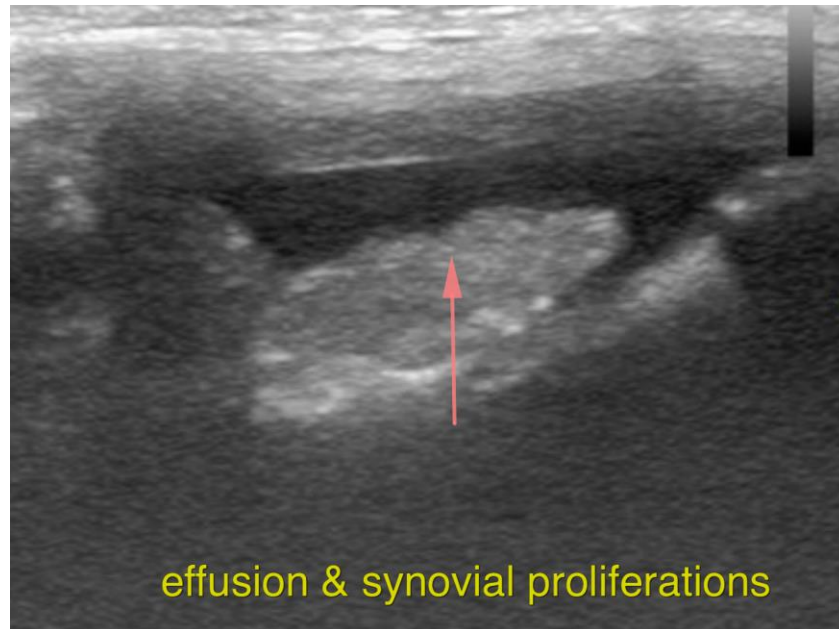
Dr. Stefanie Simon

INVOICE

56614

DATE

2-7-23





PATIENT

Lily Panensky

The information and recommendations provided are based on the images presented by the referring veterinarian/sonographer. No evaluation can be communicated regarding pathology that was not visible in the image/video clips provided.

SPECIES

Canine

Thank you for this referral. If the clinical or image interpretation does not parallel your findings or if I can be of any further assistance please contact me.

BREED

Labrador Terrier Mix

Nele Eley, DVM, Dr. med. vet., DipECVDI
European Specialist in Veterinary Diagnostic Imaging, Cert. Radiology,
Senior lecturer University of Giessen, Germany, Veterinary Faculty, Department of Radiology
Nele.Eley@sonopath.com

SEX

FS

AGE

10 Years, 11 Months

INTERPRETED BY

Nele Eley, DVM
Dr. med. Vet. DipECVDI

HOSPITAL NAME

Northvale Veterinary
Clinic

REFERRING VET

Dr. Stefanie Simon

INVOICE

56614

DATE

2-7-23