



PATIENT

Lady Daisy Bachelder

SPECIES

Canine

BREED

Corgi Cardigan Welsh

SEX

SF

AGE

4 Years, 5 Months

INTERPRETED BY

Nele Eley, DVM
Dr. med. Vet. DipECVDI

HOSPITAL NAME

DPC Veterinary
Hospital

REFERRING VET

Cepero

INVOICE

56621

DATE

2-7-23

PRESENTING CLINICAL SIGNS

4y 5m old SF Corgi presents for "dry heaving"? O reports last week pet started making dry heaving noises and took her to vet where they told her it was reverse sneezing and rx'd hydroxyzine bid x 3 days. Pet was still making noises and now o feels like it sounds like a cough. Abnormal PE/Chem/CBC/UA Results: PE all WNL

RADIOGRAPHIC STUDY OF THE THORAX

Right/left lateral and ventrodorsal views of the thorax totaling 3 images available for review.

RADIOGRAPHIC FINDINGS

Course and width of the cervical and thoracic trachea are considered within normal limits.

The lungs are moderately expanded. A moderate generalized bronchial lung pattern with peribronchial cuffing accentuating the caudodorsal lung is seen.

There is no evidence of abnormal mediastinal widening.

The cardiac silhouette presents within normal limits. The vertebral heart score is 9.1.

The stomach is postprandial.

RADIOGRAPHIC DIAGNOSIS

- Moderate caudodorsally accentuated bronchial lung pattern.

INTERPRETATION OF THE FINDINGS & FURTHER RECOMMENDATIONS

The radiographic findings suggest potential for active lower airway disease such as eosinophilic bronchopneumopathy versus infectious bronchitis including viral, bacterial, and less likely parasitic. Further definition by means of airway endoscopy with airway sampling would be ideal. A clinical trial of treatment for bronchitis and proactive deworming could be considered alternatively.



PATIENT

Lady Daisy Bachelder

SPECIES

Canine

BREED

Corgi Cardigan Welsh

SEX

SF

AGE

4 Years, 5 Months

INTERPRETED BY

Nele Eley, DVM
Dr. med. Vet. DipECVDI

HOSPITAL NAME

DPC Veterinary
Hospital

REFERRING VET

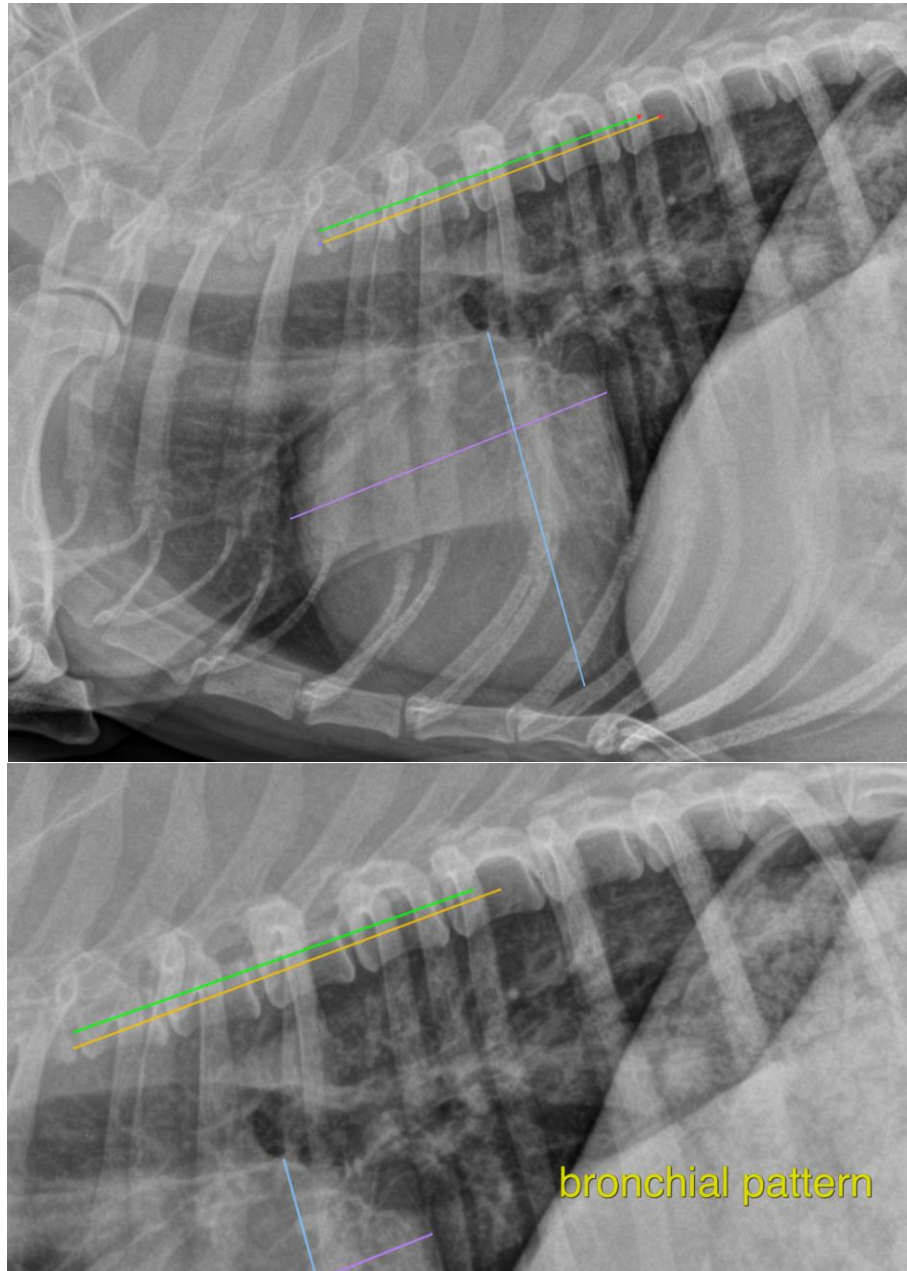
Cepero

INVOICE

56621

DATE

2-7-23





PATIENT

Lady Daisy Bachelder

The information and recommendations provided are based on the images presented by the referring veterinarian/sonographer. No evaluation can be communicated regarding pathology that was not visible in the image/video clips provided.

SPECIES

Canine

Thank you for this referral. If the clinical or image interpretation does not parallel your findings or if I can be of any further assistance please contact me.

BREED

Corgi Cardigan Welsh

Nele Eley, DVM, Dr. med. vet., DipECVDI
European Specialist in Veterinary Diagnostic Imaging, Cert. Radiology,
Senior lecturer University of Giessen, Germany, Veterinary Faculty, Department of Radiology
Nele.Eley@sonopath.com

SEX

SF

AGE

4 Years, 5 Months

INTERPRETED BY

Nele Eley, DVM
Dr. med. Vet. DipECVDI

HOSPITAL NAME

DPC Veterinary
Hospital

REFERRING VET

Cepero

INVOICE

56621

DATE

2-7-23