



**PATIENT**

Simba Vivirito

**PRESENTING CLINICAL SIGNS**

O reports lame RH but exam unremarkable except for suspected LH CCL injury/partial tear  
Abnormal PE/Chem/CBC/UA Results: N/A

**SPECIES**

Canine

**ULTRASONOGRAPHIC FINDINGS**

**Left Stifle**

The infrapatellar views of the left stifle reveal thickening, irregular outline, and altered internal echoarchitecture of the left cranial cruciate ligament. A fine hypoechoic halo is seen superficial and deep to the ligament. The infrapatellar fat pad presents mild heterogeneity. Only a mild amount of anechoic effusion is seen in the infrapatellar region of the stifle joint.

**BREED**

Golden Retriever

**ULTRASONOGRAPHIC DIAGNOSIS**

**SEX**

- Cranial cruciate ligament pathology of the left stifle.

**MN**

**INTERPRETATION OF THE FINDINGS & FURTHER RECOMMENDATIONS**

**AGE**

2 Years

The ultrasonographic findings support the presence of cranial cruciate ligament pathology in the left stifle joint. The changes are suggestive for partial rupture. Elongation and edema of the ligament cannot be ruled out entirely as differential diagnoses; however, the severity of the ultrasonographic changes is more suggestive for early partial rupture of the cranial cruciate ligament.

**INTERPRETED BY**

Nele Eley, DVM  
Dr. med. Vet. DipECVDI

**HOSPITAL NAME**

Foxfield Veterinary  
Services

**REFERRING VET**

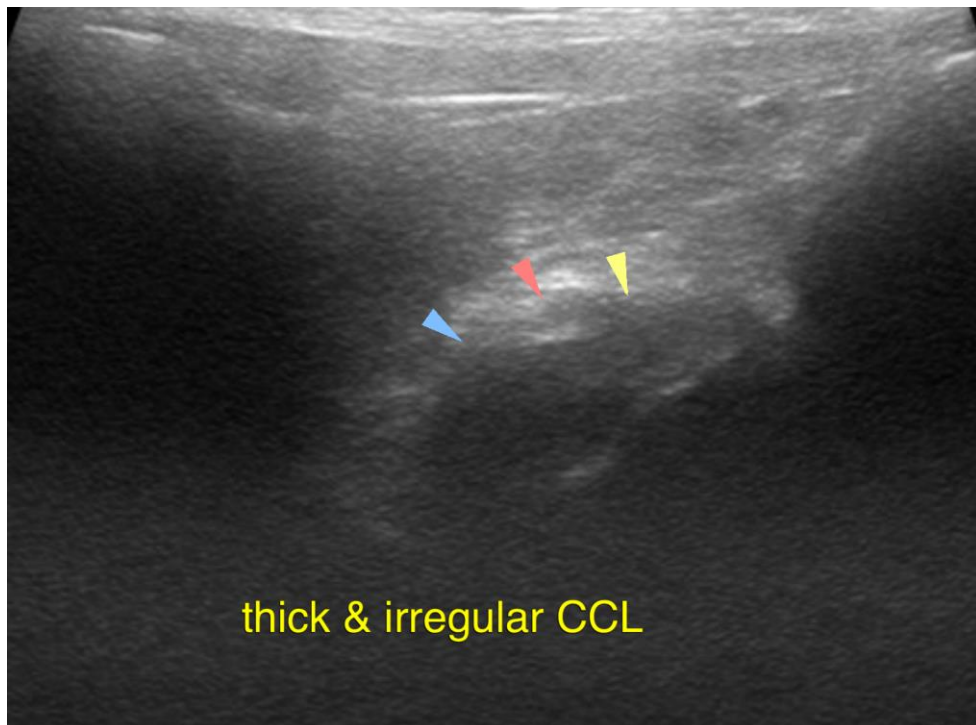
A. Rodriguez

**INVOICE**

50149

**DATE**

2-7-22





**PATIENT**

Simba Vivirito

The information and recommendations provided are based on the images presented by the referring veterinarian/sonographer. No evaluation can be communicated regarding pathology that was not visible in the image/video clips provided.

Thank you for this referral. If the clinical or image interpretation does not parallel your findings or if I can be of any further assistance please contact me.

**SPECIES**

Canine

**Nele Eley**, DVM, Dr. med. vet., DipECVDI  
European Specialist in Veterinary Diagnostic Imaging, Cert. Radiology,  
Senior lecturer University of Giessen, Germany, Veterinary Faculty, Department of Radiology  
Nele.Eley@sonopath.com

**BREED**

Golden Retriever

**SEX**

MN

**AGE**

2 Years

**INTERPRETED BY**

Nele Eley, DVM  
Dr. med. Vet. DipECVDI

**HOSPITAL NAME**

Foxfield Veterinary  
Services

**REFERRING VET**

A. Rodriguez

**INVOICE**

50149

**DATE**

2-7-22