

**PATIENT**

Maisie Murray

PRESENTING CLINICAL SIGNS

2y 11m old MN DSH presents for intermittent cough, since before last visit. Indoor only. On hairball remedy.

SPECIES

Feline

RADIOGRAPHIC STUDY OF THE THORAX

Right/left lateral and ventrodorsal views totaling 3 images available for review.

BREED

DSH

The patient is obese.

The degree of pulmonary inflation is moderate to fair on the available images. A moderate generalized bronchial lung pattern with peribronchial cuffing is noted with even distribution throughout the lung.

SEX

NM

No evidence of cardiovascular pathology is seen.

There is no evidence of abnormal mediastinal widening or mediastinal lymphadenomegaly.

AGE

2 Years, 11 Months

Course and width of the trachea are considered within normal limits

The stomach is post-prandial and presents mild aerophagia.

INTERPRETED BY

Nele Eley, DVM
Dr. med. Vet. DipECVDI

RADIOGRAPHIC DIAGNOSIS

- Moderate active lower airway pattern.

INTERPRETATION OF THE FINDINGS & FURTHER RECOMMENDATIONS**HOSPITAL NAME**

DPC Veterinary
Hospital

The radiographic findings are compatible with chronic lower airway disease. Eosinophilic/allergic lower airway syndrome is considered by far most likely. However, infectious bronchitis such as viral, bacterial, parasitic, or protozoal cannot be ruled out entirely as a differential diagnosis. Consider a clinical trial of treatment for feline asthma versus further definition by means of airway sampling.

REFERRING VET

Dr. White

INVOICE

50143

DATE

2-7-22



PATIENT

Maisie Murray

SPECIES

Feline

BREED

DSH

SEX

NM

AGE

2 Years, 11 Months

INTERPRETED BY

Nele Eley, DVM
Dr. med. Vet. DipECVDI

HOSPITAL NAME

DPC Veterinary
Hospital

REFERRING VET

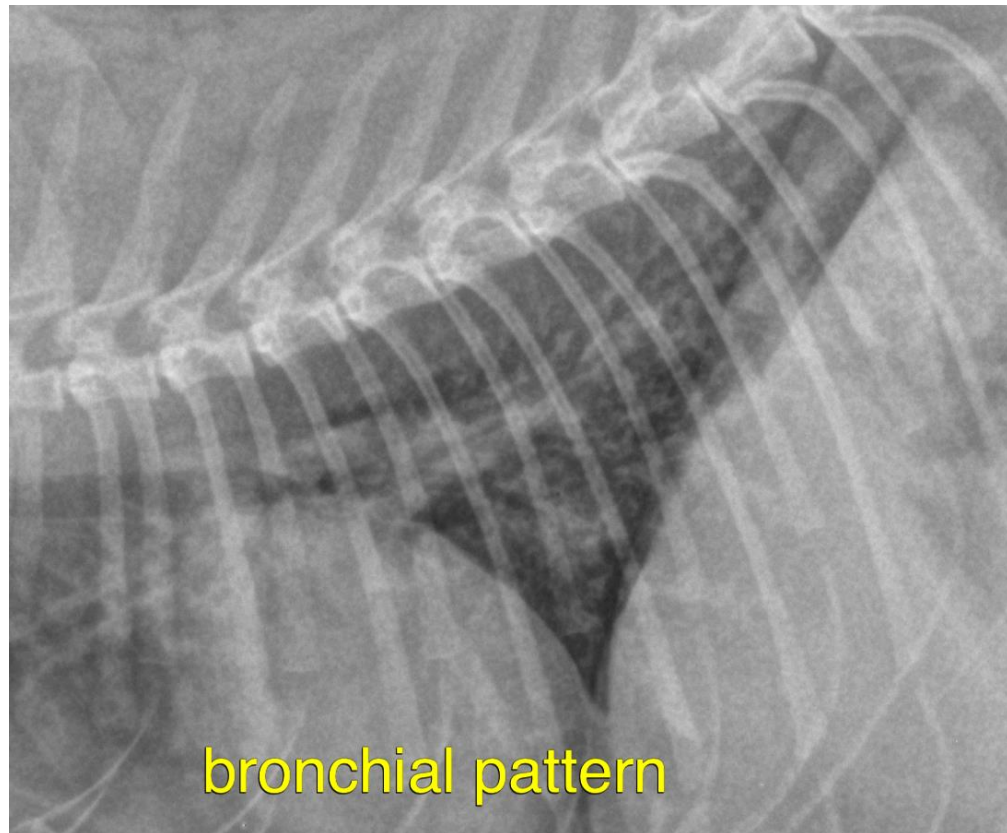
Dr. White

INVOICE

50143

DATE

2-7-22



The information and recommendations provided are based on the images presented by the referring veterinarian/sonographer. No evaluation can be communicated regarding pathology that was not visible in the image/video clips provided.

Thank you for this referral. If the clinical or image interpretation does not parallel your findings or if I can be of any further assistance please contact me.

Nele Eley, DVM, Dr. med. vet., DipECVDI
European Specialist in Veterinary Diagnostic Imaging, Cert. Radiology,
Senior lecturer University of Giessen, Germany, Veterinary Faculty, Department of Radiology
Nele.Eley@sonopath.com