

**PATIENT**

Moca Ruby

**SPECIES**

Canine

**BREED**Australian Shepherd  
Mix**SEX**

FS

**AGE**

3 Years

**INTERPRETED BY**Nele Eley, DVM  
Dr. med. Vet. DipECVDI**HOSPITAL NAME**Scottsdale Veterinary  
Clinic**REFERRING VET**

Dr Engelschall

**INVOICE**

56601

**DATE**

2-6-23

**PRESENTING CLINICAL SIGNS**

Acute onset of swelling of left eye. Was normal yesterday, when owner woke up this morning pet's left eye was swollen. No known trauma, no prior medical history, no current medications. Presented for CT scan. No apparent tooth root abscess, teeth probed normal. CBC/Chem performed 2/6/23- TP 9.9, lymphocytosis 9.97k. Tonopen: OD: 25, 26, 26mmHg, OS: 25, 25, 26mmHg. Fluorescein stain negative OU. On physical exam: OD wnl, OS buphthalmia, chemosis, elevated 3rd eyelid, small white opacity central corneal surface, normal retropulsion. No pain on opening of oral cavity.

**COMPUTED TOMOGRAPHIC STUDY OF THE HEAD**

Plain and post contrast studies available for review.

**COMPUTED TOMOGRAPHIC FINDINGS**

Mild lefthand sided exophthalmos is noted. There is no evidence of a discrete retrobulbar mass effect. However, moderate generalized ill-defined periocular soft tissue swelling with slightly increased enhancement and peripheral fat stranding is seen. There is no evidence of foreign material. The ocular structures present within normal limits.

**COMPUTED TOMOGRAPHIC DIAGNOSIS**

- Lefthand sided exophthalmos with diffuse periocular soft tissue swelling.

**INTERPRETATION OF THE FINDINGS & FURTHER RECOMMENDATIONS**

The CT findings are compatible with orbital periocular cellulitis. Periorbital pseudotumor is a potential differential diagnosis. Evidence of foreign material was not seen. Full ophthalmologic workup, however, is recommended if not performed already.



**PATIENT**

Moca Ruby

**SPECIES**

Canine

**BREED**

Australian Shepherd  
Mix

**SEX**

FS

**AGE**

3 Years

**INTERPRETED BY**

Nele Eley, DVM  
Dr. med. Vet. DipECVDI

**HOSPITAL NAME**

Scottsdale Veterinary  
Clinic

**REFERRING VET**

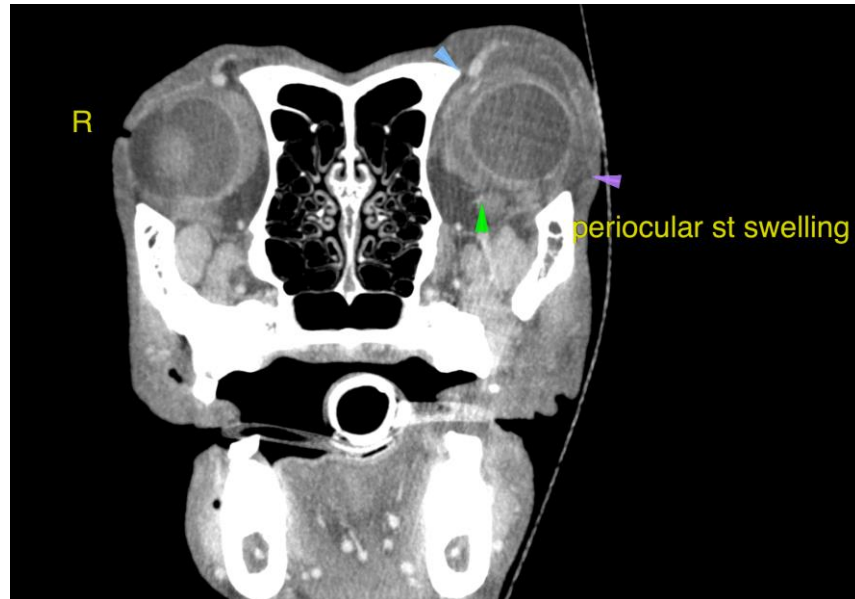
Dr Engelschall

**INVOICE**

56601

**DATE**

2-6-23



The information and recommendations provided are based on the images presented by the referring veterinarian/sonographer. No evaluation can be communicated regarding pathology that was not visible in the image/video clips provided.

Thank you for this referral. If the clinical or image interpretation does not parallel your findings or if I can be of any further assistance please contact me.

**Nele Eley**, DVM, Dr. med. vet., DipECVDI  
European Specialist in Veterinary Diagnostic Imaging, Cert. Radiology,  
Senior lecturer University of Giessen, Germany, Veterinary Faculty, Department of Radiology  
Nele.Eley@sonopath.com