



PATIENT PRESENTING CLINICAL SIGNS

Lulu Garcia 13 year old toy poodle s/f. presenting today for loosing muscle mass. p has also lost 8 pounds last visit 7-7-2020. o is only giving chicken because p wont eat dog food. drinking more water than before. has on and off diarrhea since october. had diarrhea today but was normal tomorrow.

SPECIES Abnormal PE/Chem/CBC/UA Results: CV/Respiratory: Normal heart rate and rhythm, grade III/VI L systolic murmur, pulses strong and synchronous, normal bronchovesicular sounds. EENT: OU: corneal opacities (chronic). Clear AU. No nasal discharge. No cough on tracheal palpation. Oral cavity: Missing some incisors, gingival recession on upper incisors. Moderate dental tartar

K9 Musculoskeletal: BCS = 3/9. Ambulatory x 4. Severe generalized muscle atrophy, thickened stifles with mild crepitus Uro/Perineum: No significant lesions Abd/GI: Soft, non-painful. No masses or fluid wave palpated Lymph Nodes: No peripheral lymphadenopathy Neurological: Alert and appropriate. No significant abnormalities Skin: Good hair coat. No ectoparasites seen

BREED Toy Poodle Mentation: BAR Hydration: ~5%dehydration

SEX RADIOGRAPHIC STUDY OF THE THORAX

SF Right/left lateral and ventrodorsal views totaling 3 images available for review.

RADIOGRAPHIC FINDINGS

AGE The lungs are deeply inflated. A mild generalized bronchial lung pattern with caudodorsal accentuation and mild peribronchial cuffing are seen.

11 Years Course and width of the trachea are considered within normal limits.

INTERPRETED BY

Nele Eley, DVM The cardiac silhouette is upright and thin. There is no evidence of specific chamber enlargement or overall cardiomegaly. The pulmonary vasculature is thin. The vertebral heart score is 9.4. No evidence of mediastinal widening is seen.

Dr. med. Vet. DipECVDI

HOSPITAL NAME

The thoracic boundaries are considered within normal limits.

DPC Veterinary Hospital

RADIOGRAPHIC DIAGNOSIS

- Mild lower airway pattern.
- Radiographically normal cardiac silhouette.

REFERRING VET

Dr. Rivera

INTERPRETATION OF THE FINDINGS & FURTHER RECOMMENDATIONS

The radiographic study reveals no cardiomegaly and no specific chamber enlargement. There are no signs of congestive heart failure.

INVOICE

50120

A mild bronchial lung pattern is noted which may reflect uncomplicated age related changes. Mild chronic lower airway disease cannot be ruled out entirely; however, further definition would only be indicated in case of pertinent clinical signs.

DATE

2-6-22



PATIENT

Lulu Garcia

SPECIES

K9

BREED

Toy Poodle

SEX

SF

AGE

11 Years

INTERPRETED BY

Nele Eley, DVM
Dr. med. Vet. DipECVDI

HOSPITAL NAME

DPC Veterinary
Hospital

REFERRING VET

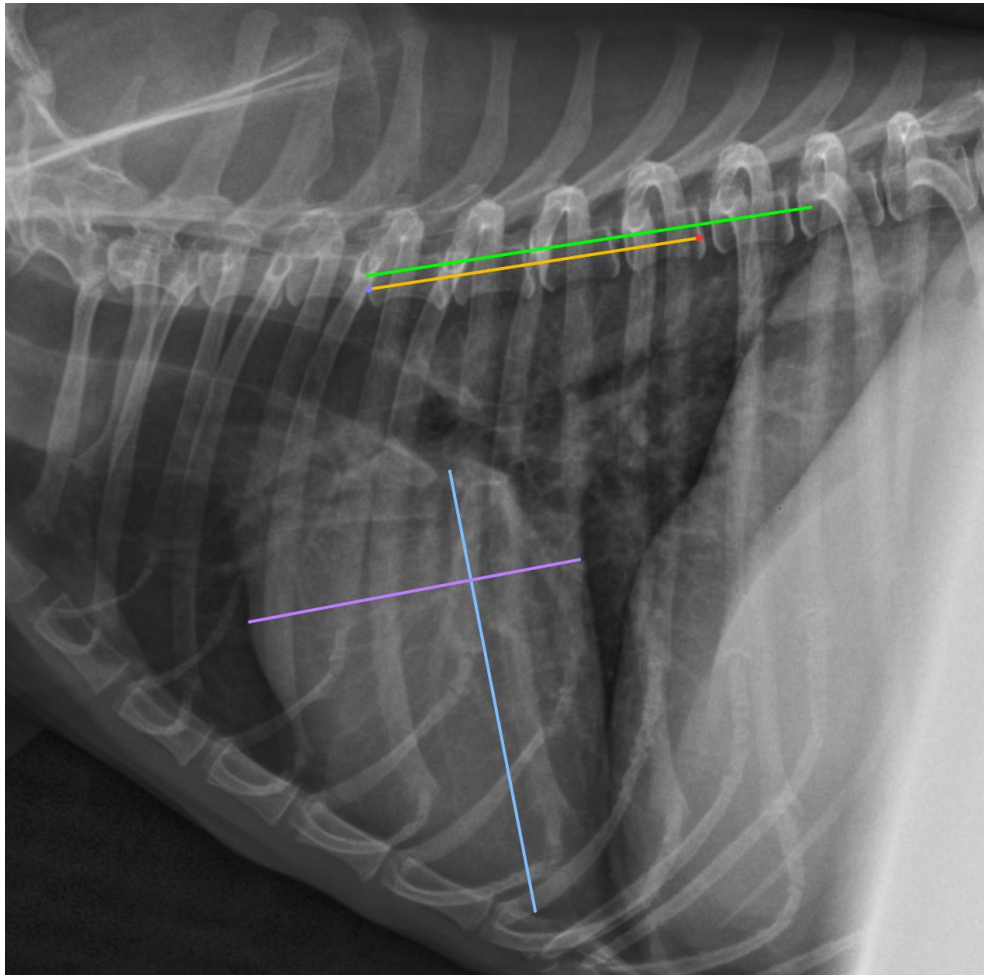
Dr. Rivera

INVOICE

50120

DATE

2-6-22



The information and recommendations provided are based on the images presented by the referring veterinarian/sonographer. No evaluation can be communicated regarding pathology that was not visible in the image/video clips provided.

Thank you for this referral. If the clinical or image interpretation does not parallel your findings or if I can be of any further assistance please contact me.

Nele Eley, DVM, Dr. med. vet., DipECVDI
European Specialist in Veterinary Diagnostic Imaging, Cert. Radiology,
Senior lecturer University of Giessen, Germany, Veterinary Faculty, Department of Radiology
Nele.Eley@sonopath.com