



PATIENT

Max Mawson

SPECIES

Canine

BREED

Labrador Retriever

SEX

M

AGE

5Y, 3M

WEIGHT

33.4kg

INTERPRETED BY

Nele Eley (Ondreka),
DVM Dr. med. vet.,
DipECVDI

IMAGING PERFORMED BY

Ana

HOSPITAL NAME

Animal Trust - Bolton

REFERRING VET

Ana Valega

INVOICE

73644

DATE

2-5-26

PRESENTING CLINICAL SIGNS

- 27/12/25 jumped over height and developed intermittent lameness RH
- Radiology Interpretation: Stifles wnl. ROM right hip reduced. Femur neck slightly thicker compared to left. Acetabulum wnl, head covers >50%. No OA changes or effusion in joints.
- No swelling, instability on any joint. Cranial drawer negative. Nothing on pads, toes, nails.
Diagnosis: poss start hip dysplasia worsened by trauma?

Abnormal PE/Chem/CBC/UA Results: WNL

COMPUTED TOMOGRAPHIC STUDY OF THE PELVIS

Plain study available for review.

COMPUTED TOMOGRAPHIC FINDINGS

Mild bilateral hip dysplasia characterized by mild incongruence of the coxofemoral joints and slightly reduced femoral head coverage is seen. Mild lateralized subchondral bone sclerosis of the acetabular grooves is present. There are mild circumferential femoral head and caudolateral curvilinear femoral neck osteophytes. No evidence of femoral head or neck fracture is seen.

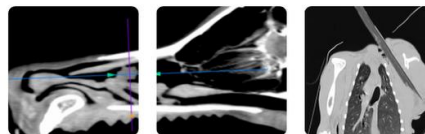
Moderate intervertebral disc protrusion is noted at the lumbosacral junction associated with spondylosis deformans and mild bilateral neuroforaminal narrowing. Additional lateralized spondylosis deformans is present at L6/7. There is no evidence of acute vertebral fracture or luxation.

COMPUTED TOMOGRAPHIC DIAGNOSIS

- Mild bilateral canine hip dysplasia with early degenerative joint disease.
- Moderate degenerative lumbosacral stenosis with associated spondylosis L6/7 and L7/S1 as well as mild to moderate lumbosacral disc protrusion.
- No CT evidence of acute traumatic injury to the pelvis or hip joints.

INTERPRETATION OF FINDINGS & FURTHER RECOMMENDATIONS

While mild bilateral hip dysplasia is present, the absence of additional signs of traumatic osseous injury suggests this may represent a chronic low grade finding that can be exacerbated temporarily by acute injury. The lumbosacral disc protrusion with neuroforaminal narrowing may contribute to intermittent hind limb lameness as well particularly following physical exertion or trauma. The recent jumping incident may have exacerbated preexisting musculoskeletal or spinal changes. Correlation with neurologic and orthopedic examination is recommended. Advanced imaging such as MRI of the lumbar spine may be considered if neurologic deficits or persistent pain develop.



PATIENT

Max Mawson

SPECIES

Canine

BREED

Labrador Retriever

SEX

M

AGE

5Y, 3M

WEIGHT

33.4kg

INTERPRETED BY

Nele Eley (Ondreka),
DVM Dr. med. vet.,
DipECVDDI

IMAGING PERFORMED BY

Ana

HOSPITAL NAME

Animal Trust - Bolton

REFERRING VET

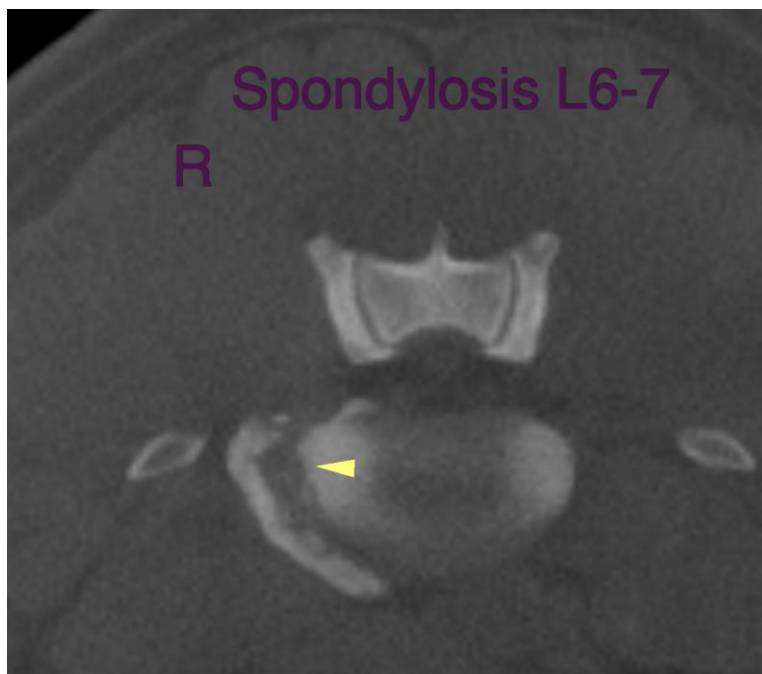
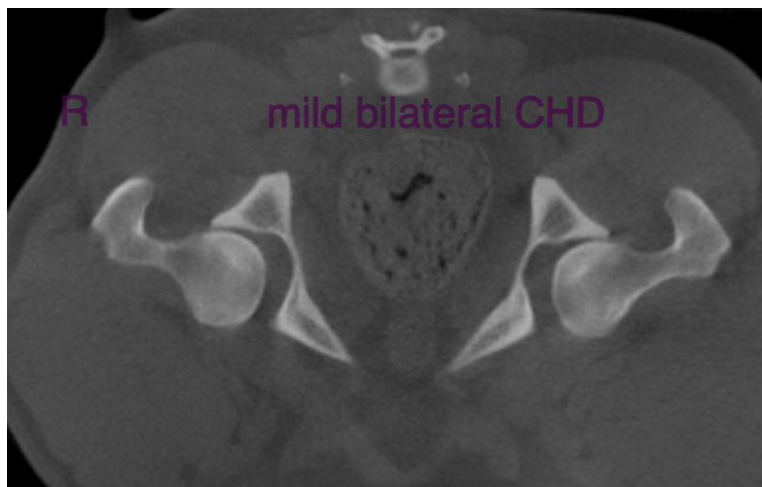
Ana Valega

INVOICE

73644

DATE

2-5-26





PATIENT

Max Mawson

SPECIES

Canine

BREED

Labrador Retriever

SEX

M

AGE

5Y, 3M

WEIGHT

33.4kg

INTERPRETED BY

Nele Eley (Ondreka),
DVM Dr. med. vet.,
DipECVDI

IMAGING PERFORMED BY

Ana

HOSPITAL NAME

Animal Trust - Bolton

REFERRING VET

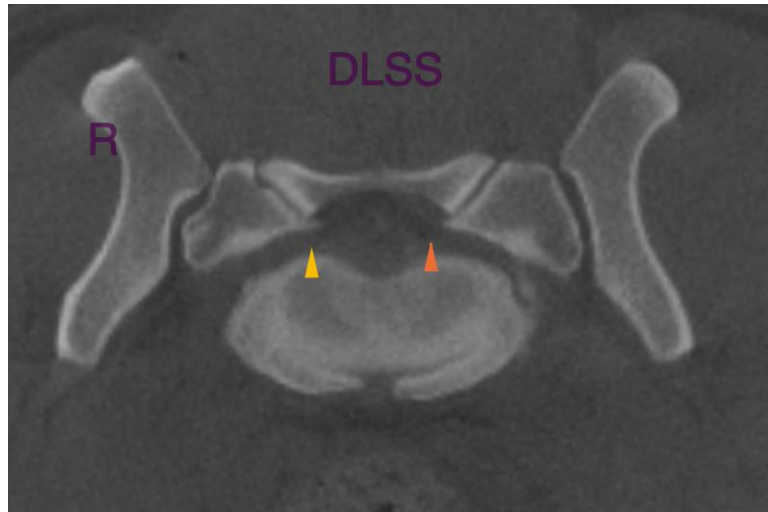
Ana Valega

INVOICE

73644

DATE

2-5-26



The information and recommendations provided are based on the images presented by the referring veterinarian. No evaluation can be communicated regarding pathology that was not visible in the image/video clips provided.

Thank you for this referral. If the clinical or image interpretation does not parallel your findings or if I can be of any further assistance please contact me.

Nele Eley (Ondreka), DVM, Dr. med. vet., DipECVDI
European Specialist in Veterinary Diagnostic Imaging, Cert. Radiology,
Senior lecturer University of Giessen/Germany, Veterinary Faculty, Department of Radiology.
info@sonopath.com