



PATIENT

Betty Bon

SPECIES

Rabbit

BREED

Rex

SEX

FS

AGE

6Y

WEIGHT

2.34kg

INTERPRETED BY

Nele Eley (Ondreka),
DVM Dr. med. vet.,
DipECVDI

IMAGING PERFORMED BY

Alexa Jones

HOSPITAL NAME

Alberta Veterinary
Dentistry

REFERRING VET

Dr. Kriti Saxena

INVOICE

73626

DATE

2-5-26

PRESENTING CLINICAL SIGNS

- Chronic (~2 year) history of dental problems resulting in sinus infections
- 3-4 months ago Hx of right sided nasal discharge - sedated exam at the pDVM found right maxillary cheek teeth were overgrown, fractured and discoloured
- suspect tooth root abscess
- Had 2 previous dental treatments for filing/extractions (Nov 2025 - extraction, Jan 2 2026 - filing)
- Pet is sneezing clear discharge daily. No increase in severity or frequency over the months. Pet is doing well at home, E/D normal, BSC appropriate, stools regular.

Abnormal PE/Chem/CBC/UA Results: None applicable

COMPUTED TOMOGRAPHIC STUDY OF THE HEAD

Plain study available for review.

COMPUTED TOMOGRAPHIC FINDINGS

The right maxillary premolar and molar teeth 106, 107, and 108 are fragmented, partially resorbed, and impacted with severe periodontal space widening and alveolar bone loss. Tooth 109 is distorted and partially resorbed also with marked periodontal space widening. There is retrograde elongation of the tooth roots extending dorsally into the right nasal cavity and right orbit associated with extensive bone destruction, turbinate destruction, as well as soft tissue and fluid accumulation within the right nasal cavity.

The occlusal surfaces of the right mandibular and maxillary premolar and molar teeth are markedly irregular with uneven crown height, spike formation, and abnormal wear patterns consistent with severe malocclusion and chronic dental disease.

The left maxillary and mandibular premolar and molar teeth appear largely within normal limits without significant periodontal or periapical pathology.

Tooth 407 is partially resorbed and impacted without marked bone destruction at this time.

Mild right sided exophthalmos is noted.

COMPUTED TOMOGRAPHIC DIAGNOSIS

- Severe chronic right sided odontogenic disease involving maxillary teeth 106-109 with advanced periodontal disease, tooth fragmentation, resorption, and impaction.
- Suspected tooth root abscessation, extensive osteolysis, and secondary involvement of the right nasal cavity and right orbit.
- Marked right sided malocclusion.
- Partial resorption and impaction of 407.

INTERPRETATION OF FINDINGS & FURTHER RECOMMENDATIONS

The CT findings explain the chronic nasal discharge and sneezing and are compatible with advanced rabbit dental disease where retrograde tooth root elongation leads to secondary rhinitis, sinusitis, and bone destruction. The unilateral predominance and degree of osseous involvement suggest a long standing progressive process. Given the extent of bone loss, dental involvement, and regional



PATIENT

Betty Bon

SPECIES

Rabbit

BREED

Rex

SEX

FS

AGE

6Y

WEIGHT

2.34kg

INTERPRETED BY

Nele Eley (Ondreka),
DVM Dr. med. vet.,
DipECVDI

IMAGING PERFORMED BY

Alexa Jones

HOSPITAL NAME

Alberta Veterinary
Dentistry

REFERRING VET

Dr. Kriti Saxena

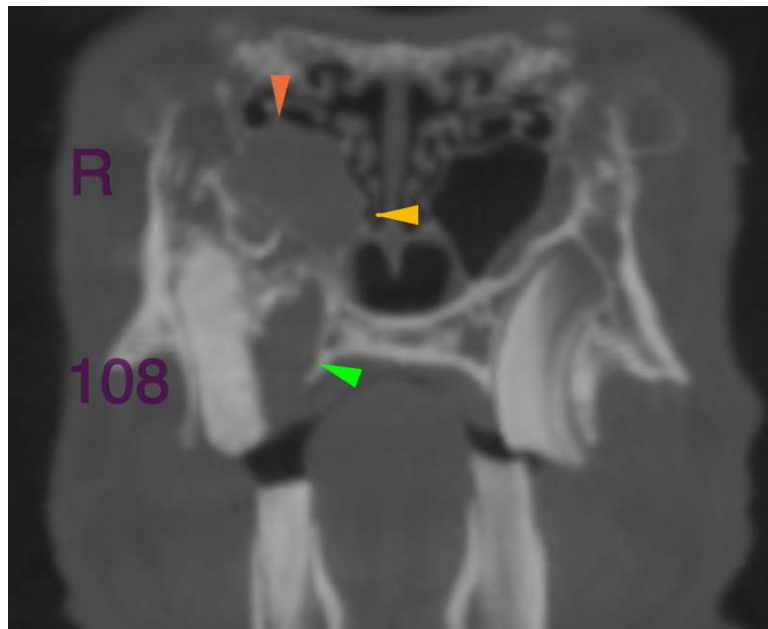
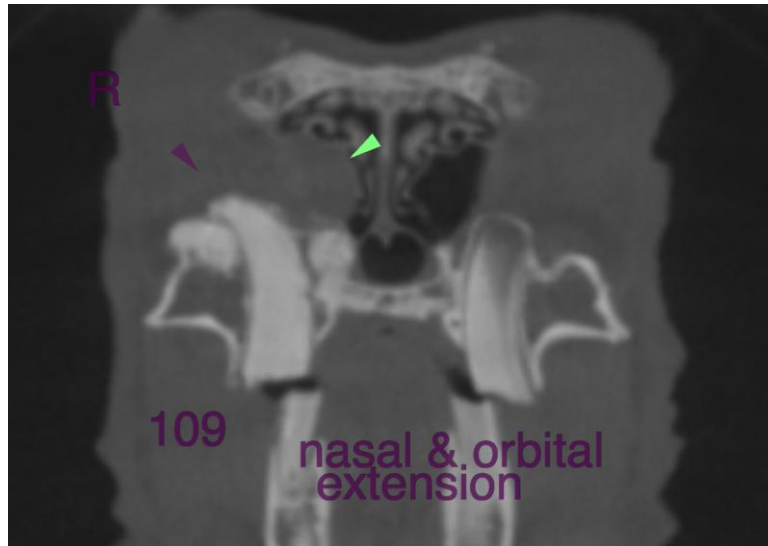
INVOICE

73626

DATE

2-5-26

extension, conservative dental management is likely to fail. Aggressive dental management potentially including extraction of the multiple severely affected right maxillary teeth has to be considered and may have to involve surgical debridement of the affected bone and associated soft tissue. Prognosis is guarded given the chronicity and extent of the disease.





PATIENT

Betty Bon

SPECIES

Rabbit

BREED

Rex

SEX

FS

AGE

6Y

WEIGHT

2.34kg

INTERPRETED BY

Nele Eley (Ondreka),
DVM Dr. med. vet.,
DipECVDI

IMAGING PERFORMED BY

Alexa Jones

HOSPITAL NAME

Alberta Veterinary
Dentistry

REFERRING VET

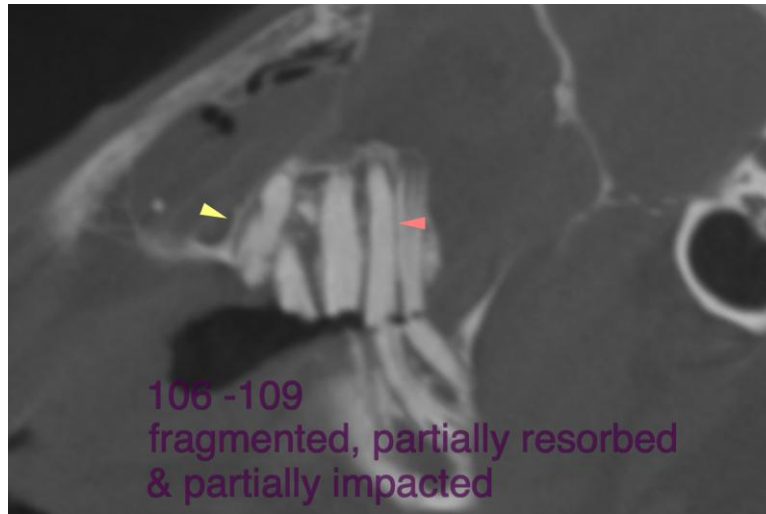Dr. Kriti Saxena

INVOICE

73626

DATE

2-5-26



The information and recommendations provided are based on the images presented by the referring veterinarian. No evaluation can be communicated regarding pathology that was not visible in the image/video clips provided.

Thank you for this referral. If the clinical or image interpretation does not parallel your findings or if I can be of any further assistance please contact me.

Nele Eley (Ondreka), DVM, Dr. med. vet., DipECVDI
European Specialist in Veterinary Diagnostic Imaging, Cert. Radiology,
Senior lecturer University of Giessen/Germany, Veterinary Faculty, Department of Radiology.
info@sonopath.com