



PATIENT

Holly Walsh

PRESENTING CLINICAL SIGNS

Holly is a 7 year old spayed Border Collie whom has a history of limping on her right front paw on and off over the last 10 days. On physical exam: BAR HP. Chest clear. No heart murmur. Limping on the right front leg- crepitus on the flexion and extension of right elbow joint

SPECIES

Canine

RADIOGRAPHIC STUDY OF THE FRONT LIMBS - SHOULDERS THROUGH CARPI

Mediolateral and caudocranial views of both shoulders, mediolateral, mediolateral supinated, and craniocaudal views of both elbows, and mediolateral and dorsopalmar views of both carpi totaling 8 images available for review.

BREED

Border Collie

RADIOGRAPHIC FINDINGS

Elbows

Blurring and decreased opacity of the medial coronoid processes are seen in both elbows. There is significant subtrochlear notch sclerosis and a large amount of periarticular new bone formation which includes the humeral trochlea, radial head, anconeus process, as well as the lateral and medial humeral epicondyles. Large osseous metaplasia is seen within the flexor origin distal of both medial humeral epicondyles.

SEX

Spayed

AGE

7 Years

Shoulders

The radiographic presentation of both shoulders is within age related normal limits.

INTERPRETED BY

Nele Eley, DVM
Dr. med. Vet. DipECVDI

Carpi

Early signs of mild degenerative joint disease are noted in both antebrachiocondylar joints.

HOSPITAL NAME

Beaches-Fallingbrook
Veterinary Clinic

RADIOGRAPHIC DIAGNOSIS

- Bilateral medial coronoid pathology with severe secondary elbow osteoarthritis and chronic flexor enthesopathy in both front limbs.

REFERRING VET

Dr Sam Shahsavari

INTERPRETATION OF THE FINDINGS & FURTHER RECOMMENDATIONS

The radiographic study reveals severe elbow osteoarthritis and chronic flexor enthesopathy of both elbows secondary to medial coronoid pathology. The severe osteoarthritic changes may be concurred by cartilage breakdown in the medial joint compartment. The flexor enthesopathy may also contribute to the clinical signs.

INVOICE

50117

DATE

2-4-22



PATIENT

Holly Walsh

SPECIES

Canine

BREED

Border Collie

SEX

Spayed

AGE

7 Years

INTERPRETED BY

Nele Eley, DVM
Dr. med. Vet. DipECVDI

HOSPITAL NAME

Beaches-Fallingbrook
Veterinary Clinic

REFERRING VET

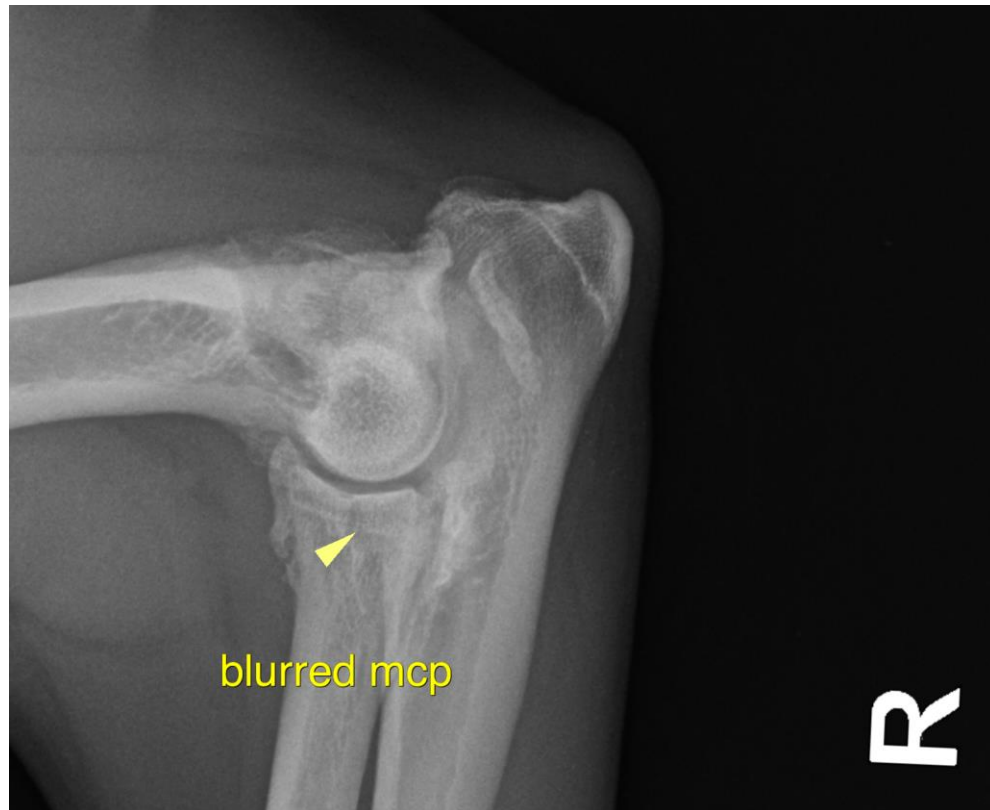
Dr Sam Shahsavari

INVOICE

50117

DATE

2-4-22



The information and recommendations provided are based on the images presented by the referring veterinarian/sonographer. No evaluation can be communicated regarding pathology that was not visible in the image/video clips provided.

Thank you for this referral. If the clinical or image interpretation does not parallel your findings or if I can be of any further assistance please contact me.

Nele Eley, DVM, Dr. med. vet., DipECVDI
European Specialist in Veterinary Diagnostic Imaging, Cert. Radiology,
Senior lecturer University of Giessen, Germany, Veterinary Faculty, Department of Radiology
Nele.Eley@sonopath.com