



PATIENT

Luka Srivastava

PRESENTING CLINICAL SIGNS

-IVDD SURGERY PERFORMED 6 YEARS AGO -HIND LIMB WEAKNESS FOR SEVERAL WEEKS
-LIMPING ON FRONT RT LIMB RECENTLY

SPECIES

Canine

COMPUTED TOMOGRAPHIC STUDY OF THE SPINE

Plain and post contrast studies available for review.

BREED

Dach

COMPUTED TOMOGRAPHIC FINDINGS

Patient has a history of prior hemilaminectomy at L2/3.

SEX

FS

A righthand sided defect is seen in the vertebral laminae and facet joint level with L2/3. A minimal amount of residual mineralized disc material is seen in the ventral epidural space with no evidence of compressive myelopathy.

AGE

10 Years

Multiple multifocal intervertebral disc mineralizations are noted.

The intervertebral disc space C3/4 presents moderate collapse. No overt disc hernia can be seen. However, there appears to be obliteration of the ventral vertebral venous plexus level with C2/3.

Moderate dilation of the lateral ventricles of the brain is noted with no evidence of active distension.

INTERPRETED BY

Nele Eley, DVM
Dr. med. Vet. DipECVDI

COMPUTED TOMOGRAPHIC DIAGNOSIS

- Suspect intervertebral disc disease C3/4.
- History of disc extrusion with hemilaminectomy L2/3 righthand sided.
- Multifocal chondroid disc degeneration.
- Ventriculomegaly of the brain - likely incidental.

HOSPITAL NAME

Green Dog Dental and
Wellness

INTERPRETATION OF THE FINDINGS & FURTHER RECOMMENDATIONS

The CT study reveals evidence of intervertebral disc disease between C3 and C4. The changes may reflect uncomplicated degenerative disc disease. However, isodense disc hernia with or without compressive myelopathy cannot be ruled out and further definition by means of a CT myelogram or an MRI is recommended in case of persisting or deteriorating clinical signs.

REFERRING VET

Garcia

No evidence of a new compressive myelopathy is noted at the prior hemilaminectomy site between L2 and L3.

INVOICE

56571

DATE

2-3-23



PATIENT

Luka Srivastava

SPECIES

Canine

BREED

Dach

SEX

FS

AGE

10 Years

INTERPRETED BY

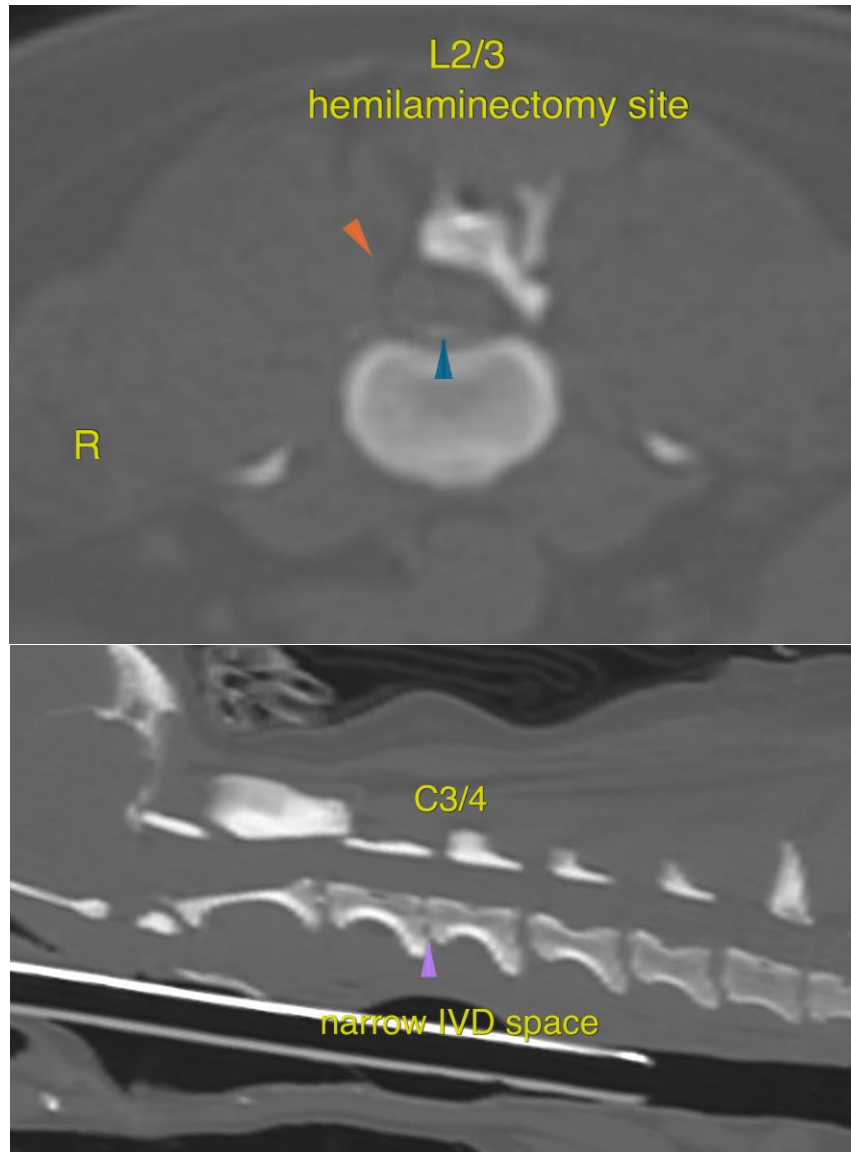
Nele Eley, DVM
Dr. med. Vet. DipECVDI

HOSPITAL NAME

Green Dog Dental and
Wellness

REFERRING VET

Garcia



The information and recommendations provided are based on the images presented by the referring veterinarian/sonographer. No evaluation can be communicated regarding pathology that was not visible in the image/video clips provided.

INVOICE

56571

Thank you for this referral. If the clinical or image interpretation does not parallel your findings or if I can be of any further assistance please contact me.

DATE

2-3-23

Nele Eley, DVM, Dr. med. vet., DipECVDI
European Specialist in Veterinary Diagnostic Imaging, Cert. Radiology,
Senior lecturer University of Giessen, Germany, Veterinary Faculty, Department of Radiology
Nele.Eley@sonopath.com