



PATIENT PRESENTING CLINICAL SIGNS

Storm Sivia Went to VCA Valley Animal Medical Center for eye exam w/ Dr. Ko. Epistaxis noted upon eye exam. Owner ops for CT to r/o foreign body , irritation, inflammation, versus fungal, versus neoplasia versus other.

SPECIES COMPUTED TOMOGRAPHIC STUDY OF THE HEAD

Canine Plain and post-contrast studies available for review.

BREED COMPUTED TOMOGRAPHIC FINDINGS

Great Dane The nasal cavities present within normal limits. There is no evidence of foreign material, turbinate destruction, mass, fluid accumulation, or mucosal swelling. However, mucosal swelling is seen within both frontal sinuses, which is more pronounced on the left side with a multiple polypoid appearance. A mild amount of fluid attenuating material is present within both frontal sinuses as well.

SEX

Neutered Male A small amount of hypoattenuating, contrast negative material is seen within the most medial aspect of both external auditory meatuses. The tympanic bullae and regional lymph nodes present within normal limits.

AGE COMPUTED TOMOGRAPHIC DIAGNOSIS

- 3 Years
- Bilateral frontal sinusitis with polypoid mucosal swelling
 - Mild bilateral otitis externa

INTERPRETED BY INTERPRETATION OF FINDINGS & FURTHER RECOMMENDATIONS

Nele Eley (Ondreka),
DVM Dr. med. vet.,
DipECVDI The CT study reveals bilateral frontal sinusitis. Differential diagnoses include infectious sinusitis such as viral, bacterial, and less likely non-infectious inflammatory sinusitis. No structural changes of the nasal cavities are seen. However, CT findings may lag behind the clinical signs here. Further definition by means of rhinoscopy with sampling can be discussed versus an attempt of symptomatic treatment with narrow clinical monitoring.

HOSPITAL NAME

Paws & Claws UC

REFERRING VET

Dr. Rambaud

INVOICE

35451

DATE

2/3/22



PATIENT

Storm Sivia

SPECIES

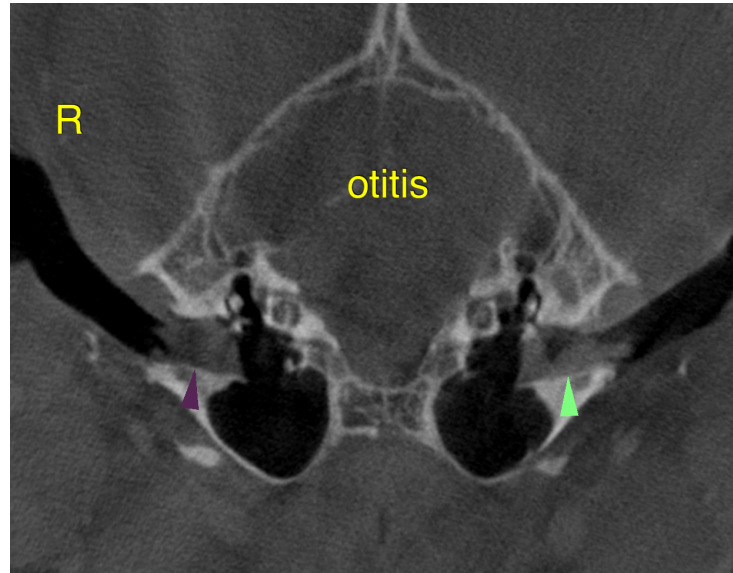
Canine

BREED

Great Dane

SEX

Neutered Male



AGE

3 Years

INTERPRETED BY

Nele Eley (Ondreka),
DVM Dr. med. vet.,
DipECVDI

HOSPITAL NAME

Paws & Claws UC

REFERRING VET

Dr. Rambaud

The information and recommendations provided are based on the images presented by the referring veterinarian. No evaluation can be communicated regarding pathology that was not visible in the image/video clips provided.

INVOICE

35451

Thank you for this referral. If the clinical or image interpretation does not parallel your findings or if I can be of any further assistance please contact me.

DATE

2/3/22

Nele Eley (Ondreka), DVM, Dr. med. vet., DipECVDI
European Specialist in Veterinary Diagnostic Imaging, Cert. Radiology,
Senior lecturer University of Giessen/Germany, Veterinary Faculty, Department of Radiology.
Nele.Eley@sonopath.com

