
PATIENT PRESENTING CLINICAL SIGNS

Prince Rodman Anorexia. Sudden crying and restlessness, especially at night. O thinks he's in pain. previous vet switched diet to selected protein. Prince started eating well but the crying didn't stop.
 Abnormal PE/Chem/CBC/UA Results: No heart murmur, strong pulse on hind legs. Blood glucose 6.4mmol/L. Blood glucose RH paw 3.7mmol/L. and LH paw 2.4mmol/L Bloodwork from previous vet showed mild increase in white blood cells.

SPECIES

Feline

RADIOGRAPHIC STUDY OF THE THORAX & ABDOMEN
BREED

Right/left lateral and ventrodorsal whole body views totaling 6 images available for review.

DSH
RADIOGRAPHIC FINDINGS
Thorax

The surrounding bony structures are within normal limits.

SEX

Neutered Male

The extrathoracic soft tissues present homogeneous without abnormalities.

AGE

20 Months

The heart is of normal size and shape and there is no evidence of cardiac chamber or vascular enlargement. The pulmonary vasculature is within normal limits.

The cranial mediastinum presents the expected soft tissue opacity. The mediastinal width is less than twice the width of the vertebral column at the same level.

INTERPRETED BY

 Nele Eley (Ondreka),
 DVM Dr. med. vet.,
 DipECVDI

The trachea is normal in diameter and presents the anticipated course. The luminal outline of the trachea is smooth.

A mild generalized bronchial lung pattern is seen and evenly distributed throughout the lung.

Mild esophageal aerophagia is seen.

HOSPITAL NAME

Truscott AH

The diaphragm is well delineated with even surface and the expected mild cranial bulging of the diaphragmatic cupola.

Abdomen

The surrounding bony structures are within normal limits.

REFERRING VET

Dr. Erini Abraham

No abnormalities of the extra-abdominal soft tissues are noted. The abdominal wall is smooth and thin.

The serosal detail is maintained throughout the peritoneal and retroperitoneal space.

INVOICE

35422

The liver is appropriate in position and size and presents uniform opacity.

The splenic head is in the anticipated position and within normal limits for size and opacity. The splenic tail is not seen.

DATE

2/2/22

Both kidneys are seen and present with normal size, shape, delineation, and opacity. The urinary bladder is in its anticipated position. No radiopaque calculi are noted throughout the upper and lower urinary tract.



PATIENT The stomach is in its anticipated position and presents normal content.

Prince Rodman The small intestinal loops are of even diameter and non-dilated. A small amount of gas is seen within the small intestinal loops and considered within normal limits.

SPECIES The colon is seen in the expected position and presents with appropriate content.

Feline

RADIOGRAPHIC DIAGNOSIS

- Mild bronchial lung pattern
- Radiographically normal abdomen

BREED

DSH

INTERPRETATION OF FINDINGS & FURTHER RECOMMENDATIONS

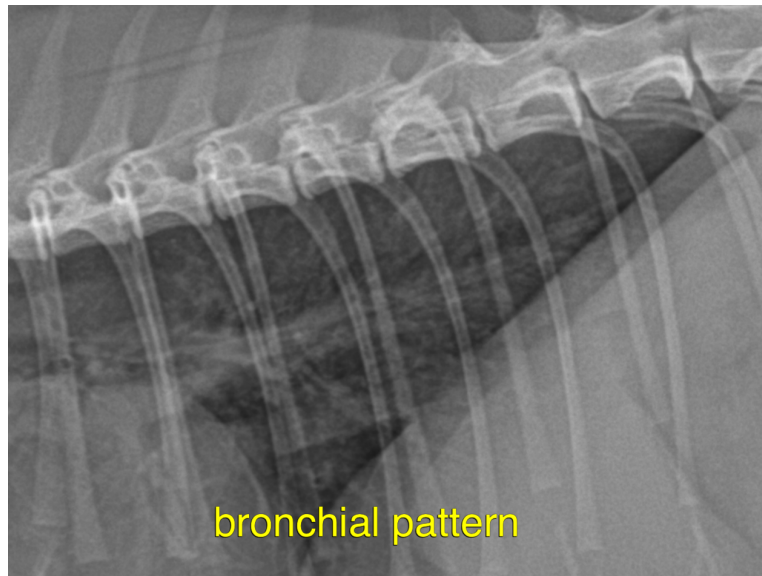
SEX

Neutered Male

The radiographic study reveals a mild bronchial lung pattern, which may indicate present or past lower airway disease such as allergic lower airway syndrome or infectious bronchitis including viral, bacterial, parasitic, or protozoal. Further definition would be indicated in case of pertinent respiratory signs. The radiographic screening of the abdomen revealed no evidence of abnormality. The thoracolumbar spine presents within normal limits.

AGE

20 Months



INTERPRETED BY

Nele Eley (Ondreka),
 DVM Dr. med. vet.,
 DipECVDI

HOSPITAL NAME

Truscott AH

REFERRING VET

Dr. Erini Abraham

The information and recommendations provided are based on the images presented by the referring veterinarian. No evaluation can be communicated regarding pathology that was not visible in the image/video clips provided.

INVOICE

35422

Thank you for this referral. If the clinical or image interpretation does not parallel your findings or if I can be of any further assistance please contact me.

DATE

2/2/22

Nele Eley (Ondreka), DVM, Dr. med. vet., DipECVDI
 European Specialist in Veterinary Diagnostic Imaging, Cert. Radiology,
 Senior lecturer University of Giessen/Germany, Veterinary Faculty, Department of Radiology.
 Nele.Eley@sonopath.com