


PATIENT PRESENTING CLINICAL SIGNS

Bella Hayes 02/02/22: L eye very swollen - unable to retropulse. Pain on oral exam when opening jaw. Susp retrobulbar abscess Patient presented with recurrent LHS swelling and LHS exophthalmia. Went down with the antibiotics but recurred again. Very difficult to intubate as jaw would not open fully. Dental 6 days ago, 208 extracted and 209 missing.

SPECIES

Canine

COMPUTED TOMOGRAPHIC STUDY OF THE HEAD & THORAX

Plain and post-contrast studies of the head, post-contrast studies of the thorax available for review.

BREED

English Bulldog

COMPUTED TOMOGRAPHIC FINDINGS
Head

Extensive soft tissue swelling with fat stranding and heterogeneous contrast enhancement is seen in the left side of the face and ventral of the left mandible.

SEX

Female

The left submandibular and medial retropharyngeal lymph nodes are moderately enlarged with maintained short to long axis ratios and contrast enhancement pattern.

AGE

10 Years

An approximately 3.0 cm sized cavitory lesion is seen in the ventrolateral and rostral aspect of the left orbita, which extends ventral of the zygomatic arch and rostral of the coronoid process of the left mandible. Thick peripheral rim enhancement is noted. There is extensive retrobulbar fat stranding and a moderate exophthalmos of the left eye. The cavitory lesion ventral of the zygomatic arch and rostral of the coronoid process of the left mandible is in direct contact with the enlarged and ill-defined left zygomatic gland. No evidence of foreign material is seen.

INTERPRETED BY

Nele Eley (Ondreka),
 DVM Dr. med. vet.,
 DipECVDI

The triadans #208 and 209 have been removed. A remnant of the distal buccal root of the triadan #209 is seen. No evidence of a dental nasal fistula or concurrent rhinitis is noted.

Thorax

Extensive motion induced streak artifacts are present, which limits the assessment. However, a generalized bronchial lung pattern with multiple peribronchial interstitial infiltrates is seen.

HOSPITAL NAME

Animal Trust –
 Ellesmere Port

COMPUTED TOMOGRAPHIC DIAGNOSIS

- Cavitory lesion with extensive peripheral cellulitis ventral of the left zygomatic arch and rostral of the left mandibular coronoid process with orbital extension and exophthalmos
- Sialadenitis of the left zygomatic gland
- Lymphadenitis of the left submandibular and retropharyngeal lymph nodes
- Bronchointerstitial lung pattern

REFERRING VET

Dr. Laura Hughes

INTERPRETATION OF FINDINGS & FURTHER RECOMMENDATIONS
INVOICE

35442

Differential diagnoses include infected or ruptured sialocele of the left zygomatic gland versus abscess. Further definition by means of aspiration and analysis of the cavitory lesion's content is recommended. The lymph node changes are compatible with reactive lymphadenitis.

DATE

2/3/22

Differential diagnoses for the bronchopulmonary changes are infectious bronchopneumonia versus eosinophilic bronchopneumopathy. Consider further definition by means of lower airway endoscopy with airway sampling.


PATIENT

Bella Hayes

SPECIES

Canine

BREED

English Bulldog

SEX

Female

AGE

10 Years

INTERPRETED BY

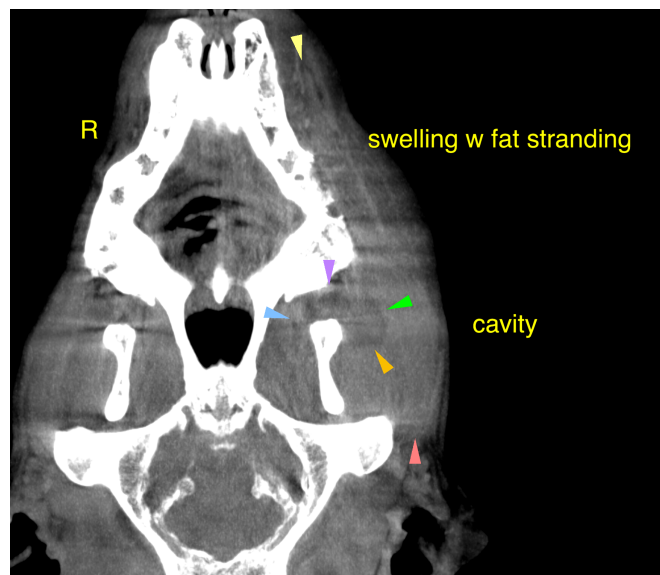
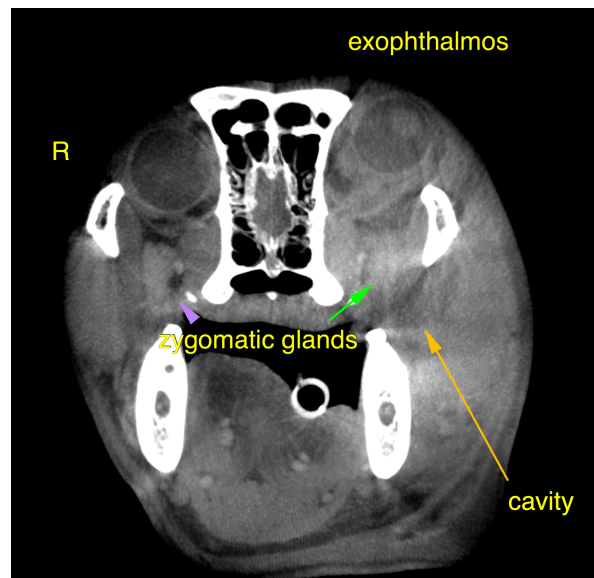
 Nele Eley (Ondreka),
 DVM Dr. med. vet.,
 DipECVDI

HOSPITAL NAME

 Animal Trust –
 Ellesmere Port

REFERRING VET

Dr. Laura Hughes



The information and recommendations provided are based on the images presented by the referring veterinarian. No evaluation can be communicated regarding pathology that was not visible in the image/video clips provided.

INVOICE

35442

DATE

2/3/22

Thank you for this referral. If the clinical or image interpretation does not parallel your findings or if I can be of any further assistance please contact me.

Nele Eley (Ondreka), DVM, Dr. med. vet., DipECVDI
 European Specialist in Veterinary Diagnostic Imaging, Cert. Radiology,
 Senior lecturer University of Giessen/Germany, Veterinary Faculty, Department of Radiology.
 Nele.Eley@sonopath.com