

**PATIENT**

Oliver Walker

**SPECIES**

Canine

**BREED**

Mix

**SEX**

Neutered Male

**AGE**

4 Years

**INTERPRETED BY**Nele Eley, DVM  
Dr. med. Vet. DipECVDF**HOSPITAL NAME**Ahwatukee Commons  
Veterinary Hospital**REFERRING VET**Dr. Rebecca R.  
Housley**INVOICE**

50605

**DATE**

2-28-22

**PRESENTING CLINICAL SIGNS**

Pt presented with limping on right front leg on 2/14/22, Owner states that Pt has issues jumping up and down. Owner noticed about 2-3 weeks ago from initial exam, but states that Pt's issues have gotten worse. Owner also mentioned Pt has allowed him to look at leg and feel the area. During ROM crepitus noted in the carpus region. No pain elicited during ROM. Per owner no traumatic events prior to onset of limping. He is indoor/outdoor. Issue has not resolved since initial exam on 2/14/22. Desert profile sent 2/16/22- valley fever came back negative.

**RADIOGRAPHIC STUDY OF THE RIGHT ELBOW**

Mediolateral and craniocaudal views of the right elbow totaling 8 images available for review.

**RADIOGRAPHIC FINDINGS**

The radiographic study reveals blurring and decreased opacity of the medial coronoid process with subtrochlear notch sclerosis of the ulnar and a mild radioulnar step formation. A mild amount of osteophytes are seen in the cranial head of the radius and on the proximal contour of the anconeus process. Blurring of the caudal contour of the lateral humeral epicondyle is seen.

**RADIOGRAPHIC DIAGNOSIS**

- Medial coronoid pathology and mild secondary osteoarthritis of the right elbow.

**INTERPRETATION OF THE FINDINGS & FURTHER RECOMMENDATIONS**

The radiographic findings are compatible with medial coronoid disease in the right elbow. Mild signs of secondary osteoarthritis are present in the right elbow. Clinical correlation is required. Further definition by means of CT and arthroscopic revision of the right elbow could be considered.



**PATIENT**

Oliver Walker

**SPECIES**

Canine

**BREED**

Mix

**SEX**

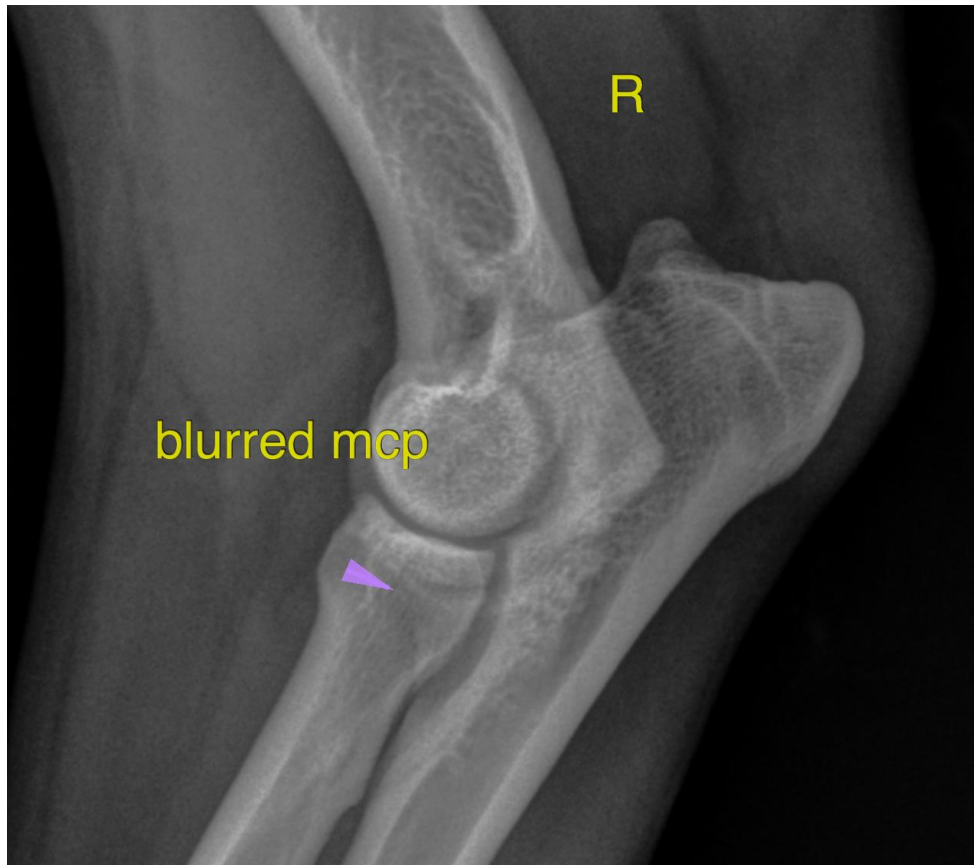
Neutered Male

**AGE**

4 Years

**INTERPRETED BY**

Nele Eley, DVM  
Dr. med. Vet. DipECVDI



**HOSPITAL NAME**

Ahwatukee Commons  
Veterinary Hospital

**REFERRING VET**

Dr. Rebecca R.  
Housley

**INVOICE**

50605

**DATE**

2-28-22

The information and recommendations provided are based on the images presented by the referring veterinarian/sonographer. No evaluation can be communicated regarding pathology that was not visible in the image/video clips provided.

Thank you for this referral. If the clinical or image interpretation does not parallel your findings or if I can be of any further assistance please contact me.

**Nele Eley**, DVM, Dr. med. vet., DipECVDI  
European Specialist in Veterinary Diagnostic Imaging, Cert. Radiology,  
Senior lecturer University of Giessen, Germany, Veterinary Faculty, Department of Radiology  
Nele.Eley@sonopath.com