



**PATIENT**

Zoey Brown

**PRESENTING CLINICAL SIGNS**

Patient developed a cough about 6 weeks ago and has had difficulty breathing. Radiographs from RDVM showed a possible mass on the lung. Patient was treated for pneumonia with multiple courses of antibiotics. Patient was referred for a CTScan to evaluate the possible mass on the lung

**SPECIES**

Canine

Abnormal PE/Chem/CBC/UA Results: Labwork showed no abnormalities

**BREED**

Pug

**COMPUTED TOMOGRAPHIC STUDY OF THE THORAX & ABDOMEN**

Post-contrast study only available for review. Multiple motion related streak artifacts are seen throughout the thorax and abdomen.

**SEX**

SF

**COMPUTED TOMOGRAPHIC FINDINGS**

**Thorax**

Moderate generalized atelectasis of the right lung is seen with the exception of the right middle lobe. The right middle lobe presents a lobar alveolar sign with mass effect and multifocal mineralizations. Heterogeneous contrast enhancement is noted. The remainder of the lung presents within age related normal limits. There is no evidence of pleural effusion or lobar torsion. The mediastinal lymph nodes present within normal limits.

**AGE**

13

**Abdomen**

**INTERPRETED BY**

Nele Eley, DVM  
Dr. med. Vet. DipECVDI

The abdominal study reveals mild generalized enlargement of the liver with slightly rounded lobar margins. The moderately distended gallbladder contains a mild amount of mineral attenuating sediment.

Both adrenal glands are plump in appearance and present mild symmetric and generalized enlargement with a pole diameter of 8mm for the cranial and caudal pole on the left side and caudal pole on the right side.

**HOSPITAL NAME**

Wilvet Salem

**COMPUTED TOMOGRAPHIC DIAGNOSIS**

**REFERRING VET**

C. Ebert

- Lobar alveolar sign with mass effect and mineralizations of the right middle lobe.
- Mild bilateral adrenomegaly.
- Mild hepatomegaly.
- Biliary microlithiasis.

**INVOICE**

50542

**INTERPRETATION OF THE FINDINGS & FURTHER RECOMMENDATIONS**

The CT study confirms presence of a mass effect within the lung. The right middle lobe presents a lobar sign with mass effect and mineralizations. Primary differential diagnosis is lobar neoplasia such as primary neoplasia of the lung including carcinoma, secondary neoplasia of the lung such as round cell neoplasia, and other. Lobar pneumonia cannot be ruled out entirely as a differential diagnosis but is thought less likely based on the CT findings. Final diagnosis will require sampling. Ultrasound guided sampling using a right parasternal intercostal approach could be considered for further definition and discussed versus direct lung lobectomy of the right middle lobe since the remainder of the lung presents no evidence of additional nodules or masses at this point.

**DATE**

2-24-22



**PATIENT**

Zoey Brown

The adrenomegaly is bilaterally symmetric and mild. Normal variant, stress induced hyperplasia, and functional hyperplasia all are a potential. Correlate with the laboratory values and consider further laboratory testing for further definition if indicated.

**SPECIES**

Canine

Differential diagnosis for the hepatomegaly includes metabolic/endocrine hepatopathy. Diffuse inflammatory/infectious or neoplastic infiltrates can never be ruled out entirely but are thought less likely based on the CT findings.

**BREED**

Pug

**SEX**

SF

**AGE**

13

**INTERPRETED BY**

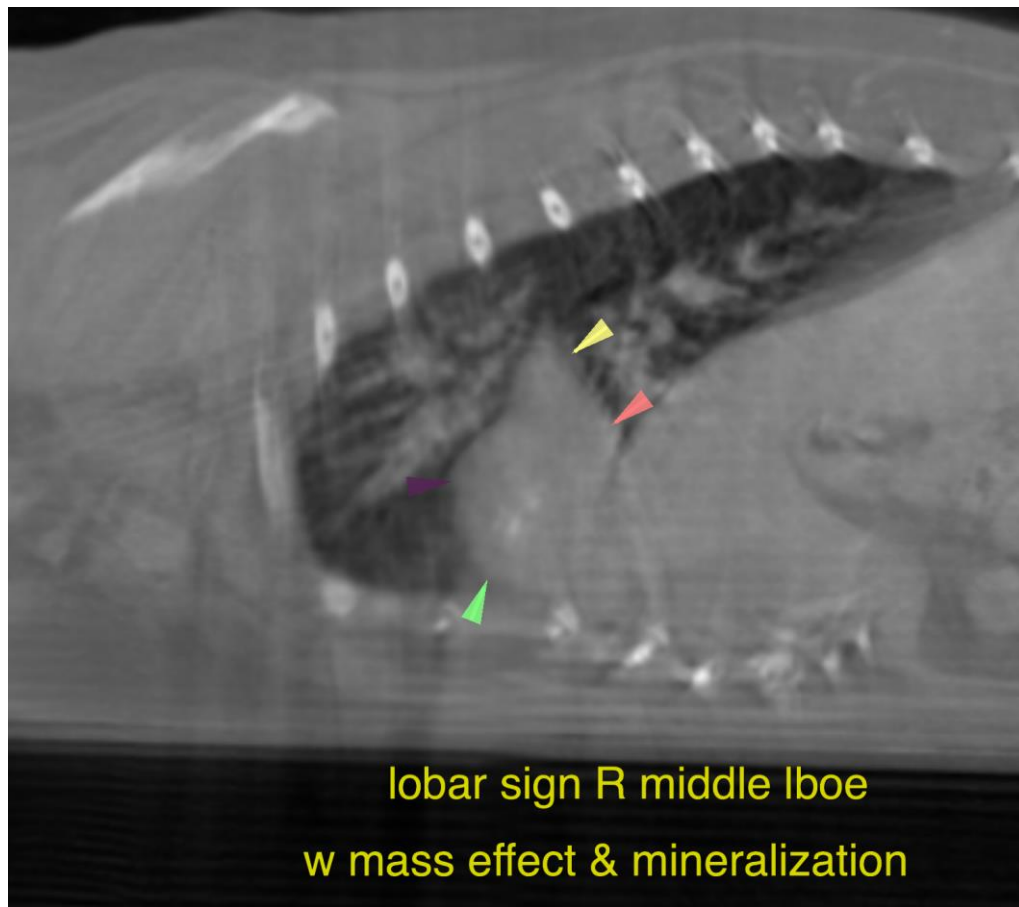
Nele Eley, DVM  
Dr. med. Vet. DipECVDI

**HOSPITAL NAME**

Wilvet Salem

**REFERRING VET**

C. Ebert



**INVOICE**

50542

The information and recommendations provided are based on the images presented by the referring veterinarian/sonographer. No evaluation can be communicated regarding pathology that was not visible in the image/video clips provided.

**DATE**

2-24-22

Thank you for this referral. If the clinical or image interpretation does not parallel your findings or if I can be of any further assistance please contact me.

**Nele Eley**, DVM, Dr. med. vet., DipECVDI  
European Specialist in Veterinary Diagnostic Imaging, Cert. Radiology,  
Senior lecturer University of Giessen, Germany, Veterinary Faculty, Department of Radiology  
Nele.Eley@sonopath.com