



**PATIENT PRESENTING CLINICAL SIGNS**

**PATIENT** Toby Chamberlain  
**SPECIES** Feline  
**BREED** DSH  
**SEX** M  
**AGE** 7.5 Years

23.2.22 - suspected unknown trauma to the face vs. neoplastic process Sneezing blood clots from L nostril. Mild skin tent. L eye - hyphaema, unable to see beyond the anterior chamber at all. no menace. unable to elicit PLR. appears meiotic but hard to see much due to blood clot taking up most of anterior chamber. swollen eyelid with bruising over left eyelid suggesting trauma most likely. R eye pressure 17mm / L eye 14mm No fluorescein uptake Head CT scan performed for further assessment - trauma vs. neoplasia vs. intracranial disease ?  
 Abnormal PE/Chem/CBC/UA Results: PCV/TP (25/2/22) - 19/75 Suspect non-regenerative anaemia

**COMPUTED TOMOGRAPHIC STUDY OF THE HEAD**

Plain and post contrast studies available for review.

**COMPUTED TOMOGRAPHIC FINDINGS**

Multiple comminuted facial bone fractures are seen accentuating the left maxillary, palatal, nasal, and frontal bones as well as the left bony orbita. Fractures extend into the hamulus of the pterygoid as well. No evidence of fracture of the neurocranium. No evidence of temporomandibular joint or mandibular injury is seen. The left maxillary alveolar crest presents moderate ventral and mild lateral deviation owing to a longitudinal fracture of the palatal and maxillary bones. The hard palate is deviated ventrally.

The left nasal cavity is filled with a large amount of fluid attenuating material which extends into the nasal fundus and left frontal sinus.

Distortion of the anatomy of the left eye is seen. The left zygomatic arch presents a longitudinal fracture with minimal displacement.

The tympanic bullae and ear canals present within normal limits.

The skull base presents within normal limits.

**COMPUTED TOMOGRAPHIC DIAGNOSIS**

- Multiple traumatic and comminuted fractures of the left facial bones involving the maxillary, nasal, frontal, and palatal bones as well as the alveolar crest of the left maxilla and the left zygomatic arch.
- Nasal and frontal sinus hemorrhage.
- Distortion of the left eye with suspect sclera rupture.

**INTERPRETATION OF THE FINDINGS & FURTHER RECOMMENDATIONS**

The CT study is compatible with multiple traumatic osseous injury of the facial bones involving the left maxillary, nasal, frontal, and palatal bones, as well as the left zygomatic arch and orbita. The findings suggest traumatic injury of the left eye with defect in the sclera. The material within the left nasal cavity and frontal sinus is compatible with blood or organizing hematoma. No evidence of temporomandibular joint involvement, mandibular fractures, or involvement of the neurocranium is seen.

**INTERPRETED BY**

Nele Eley, DVM  
 Dr. med. Vet. DipECVDI

**HOSPITAL NAME**

Colyton Veterinary  
 Hospital

**REFERRING VET**

Dalton Nguyen

**INVOICE**

50556

**DATE**

2-24-22



**PATIENT**

Toby Chamberlain

**SPECIES**

Feline

**BREED**

DSH

**SEX**

M

**AGE**

7.5 Years

**INTERPRETED BY**

Nele Eley, DVM  
Dr. med. Vet. DipECVDI

**HOSPITAL NAME**

Colyton Veterinary  
Hospital

**REFERRING VET**

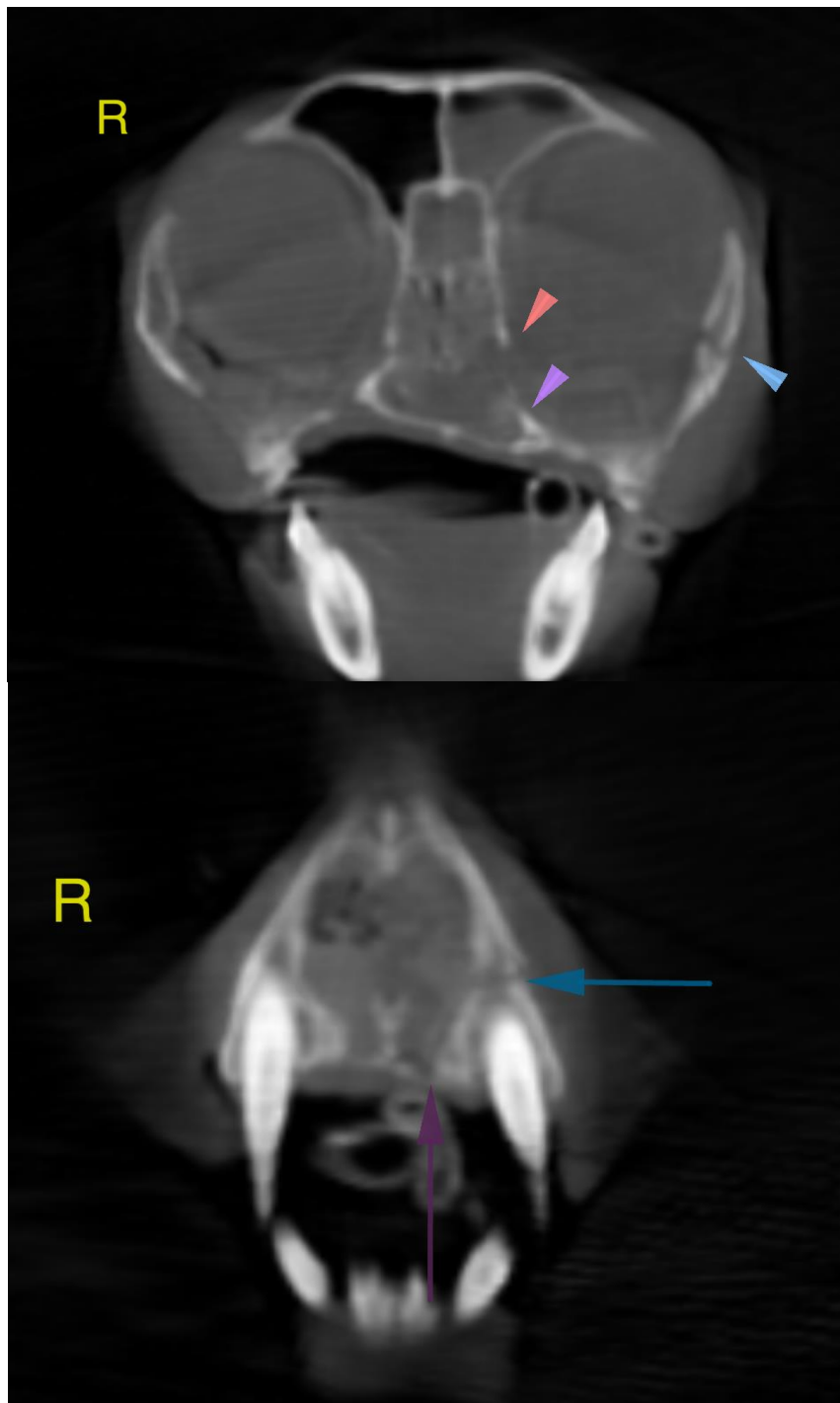
Dalton Nguyen

**INVOICE**

50556

**DATE**

2-24-22





**PATIENT**

Toby Chamberlain

The information and recommendations provided are based on the images presented by the referring veterinarian/sonographer. No evaluation can be communicated regarding pathology that was not visible in the image/video clips provided.

Thank you for this referral. If the clinical or image interpretation does not parallel your findings or if I can be of any further assistance please contact me.

**SPECIES**

Feline

**Nele Eley**, DVM, Dr. med. vet., DipECVDI  
European Specialist in Veterinary Diagnostic Imaging, Cert. Radiology,  
Senior lecturer University of Giessen, Germany, Veterinary Faculty, Department of Radiology  
Nele.Eley@sonopath.com

**BREED**

DSH

**SEX**

M

**AGE**

7.5 Years

**INTERPRETED BY**

Nele Eley, DVM  
Dr. med. Vet. DipECVDI

**HOSPITAL NAME**

Colyton Veterinary  
Hospital

**REFERRING VET**

Dalton Nguyen

**INVOICE**

50556

**DATE**

2-24-22