



PATIENT

Tatum Croghan

SPECIES

Canine

BREED

Pomeranian

SEX

Neutered

AGE

11M

WEIGHT

8.2

INTERPRETED BY

Nele Eley (Ondreka),
DVM Dr. med. vet.,
DipECVDI

IMAGING PERFORMED BY

Carissa Hayden

HOSPITAL NAME

Elizabeth Animal
Hospital

REFERRING VET

Jennifer Redus, DVM

INVOICE

73913

DATE

2-23-26

PRESENTING CLINICAL SIGNS

- He is limping on his left hind leg
- He doesn't seem to be slowing down by it.
- The limping will come and go.

Abnormal PE/Chem/CBC/UA Results: PE: Healthy other than the left hind pops and seems to be very sore. No recent blood work.

RADIOGRAPHIC STUDY OF THE PELVIS & STIFLES

Mediolateral and craniocaudal views of the stifles and lateral and ventrodorsal views of the pelvis totaling 6 images available for review.

RADIOGRAPHIC FINDINGS

Left Stifle

Medial displacement of the patella consistent with medial patella luxation is seen. Mild articular soft tissue swelling is present. Early remodeling of the femoral trochlea ridges is seen.

Right Stifle

The right stifle presents normal alignment of the patella within the trochlear groove. No osseous or articular abnormalities are identified.

Pelvis

Normal conformation of the pelvic bones is noted.

The coxofemoral joints are congruent with deeply set femoral heads and no evidence of dysplasia or degenerative joint disease.

RADIOGRAPHIC DIAGNOSIS

- Left medial patella luxation with early secondary osteoarthritic changes.
- Radiographically normal right stifle and pelvis.

INTERPRETATION OF FINDINGS & FURTHER RECOMMENDATIONS

The findings are consistent with medial patella luxation of the left stifle joint which is a common condition in small breed dogs. Correlation with the orthopedic evaluation to determine clinical grading and need for stabilization is recommended. Surgical correction may be indicated to prevent progression of degenerative joint disease.

Note that the apophyseal growth plates of the tibial tuberosities are not fully ossified yet which may be important for potential future surgery.



PATIENT

Tatum Croghan

SPECIES

Canine

BREED

Pomeranian

SEX

Neutered

AGE

11M

WEIGHT

8.2

INTERPRETED BY

Nele Eley (Ondreka),
DVM Dr. med. vet.,
DipECVDI

IMAGING PERFORMED BY

Carissa Hayden

HOSPITAL NAME

Elizabeth Animal
Hospital

REFERRING VET

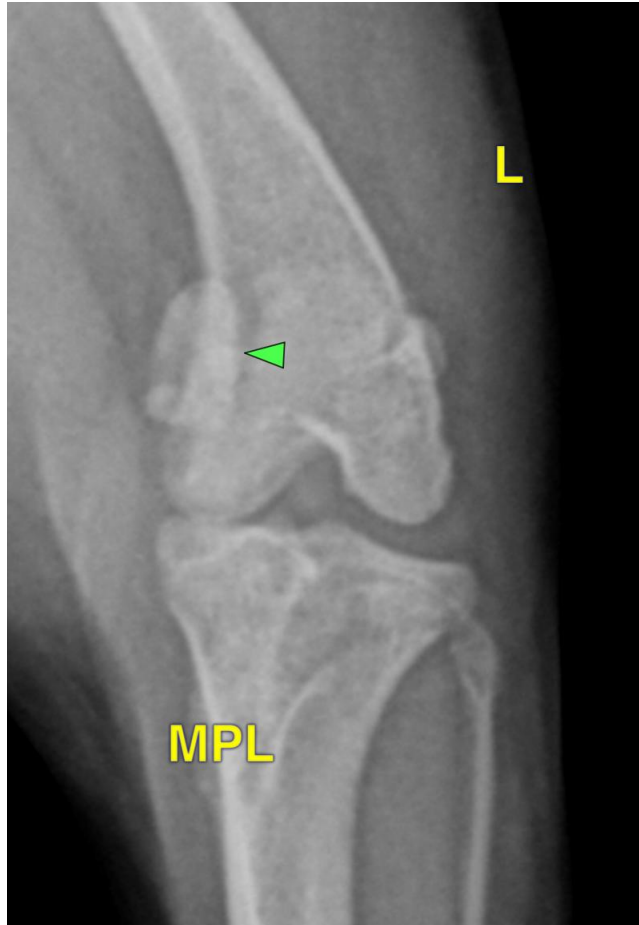
Jennifer Redus, DVM

INVOICE

73913

DATE

2-23-26



The information and recommendations provided are based on the images presented by the referring veterinarian. No evaluation can be communicated regarding pathology that was not visible in the image/video clips provided.

Thank you for this referral. If the clinical or image interpretation does not parallel your findings or if I can be of any further assistance please contact me.

Nele Eley (Ondreka), DVM, Dr. med. vet., DipECVDI

European Specialist in Veterinary Diagnostic Imaging, Cert. Radiology,
Senior lecturer University of Giessen/Germany, Veterinary Faculty, Department of Radiology.

info@sonopath.com