



PATIENT

Sami Moore

SPECIES

Canine

BREED

Poodle

SEX

Female

AGE

1Y

WEIGHT

7.5lbs

INTERPRETED BY

Nele Eley (Ondreka),
DVM Dr. med. vet.,
DipECVDI

IMAGING PERFORMED BY

Mobile Pet Imaging

HOSPITAL NAME

Mobile Pet Imaging

REFERRING VET

Novoa

INVOICE

73899

DATE

2-23-26

PRESENTING CLINICAL SIGNS

- Patient was presented for routine bloodwork (2/2/26) before spay. The report showed liver enzymes levels elevated: ALT 721 U/L (10 - 125), ALKP 900 U/L (23 - 212), GGT 24 U/L (0 - 11). Posterior abnormal Bile Acid Test (2/2/26) suggested a possible liver shunt [Preprandial 56.4 (0.0 - 14.9 µmol/L), Postprandial 100.9 (0.0 - 29.9 µmol/L)]. The CT was requested to rule out a Liver shunt.

Abnormal PE/Chem/CBC/UA Results: PE: T. 102.5 F, HR 138, RR 30, MM Pink, CRT <2 seg, H/L WNL, Dental Calculus (3/4), Retained deciduous teeth (upper canines), Focal alopecia with hyperpigmentation on the right paralumbar flank.

COMPUTED TOMOGRAPHIC STUDY OF THE ABDOMEN

The serosal fat presents normal attenuation behavior. There is no evidence of peritoneal effusion or peritonitis.

Both kidneys present within normal limits for size, shape and organ architecture. After contrast administration, a bilaterally symmetric and uniform nephro- and pyelogram is noted.

The adrenal glands are within normal limits for size, shape and organ architecture.

Both liver and spleen present with normal shape, even surface, uniformly attenuating parenchyma and homogeneous contrast enhancement, unremarkable.

The portal vein presents a normal order of its tributary veins and intrahepatic branching. No abnormal vessel is noted inside and outside of the liver parenchyma.

The pancreas is evenly contoured; the pancreatic parenchyma is homogeneous and presents uniform contrast enhancement.

The position, delineation, wall and content of the gastrointestinal tract are considered within normal limits throughout.

The bony and surrounding soft tissue structures reveal no abnormalities.

COMPUTED TOMOGRAPHIC DIAGNOSIS

- Structurally normal abdomen
- No evidence of macroscopic portosystemic shunting - neither intra- nor extrahepatic

INTERPRETATION OF THE FINDINGS & FURTHER RECOMMENDATIONS

No macroscopic vascular bypass of the liver was noted in the pre- and post-contrast studies of the abdomen. However, if the clinical signs are consistent with insufficiency of the liver, primary non-cirrhotic portal hypertension (microvascular dysplasia) or other diffuse parenchymal liver disease would still be a potential and should be ruled out by means of ultrasound guided or surgical liver biopsy.

In general ultrasound guided Tru-cut biopsies of the liver may be performed with reasonably low potential for complications under the following conditions: platelet count > 50*103/µl, <25% prolongation of PT/PTT - less of deviation from normal values acceptable in presence of peritoneal



PATIENT

Sami Moore

SPECIES

Canine

BREED

Poodle

SEX

Female

AGE

1Y

WEIGHT

7.5lbs

INTERPRETED BY

Nele Eley (Ondreka),
DVM Dr. med. vet.,
DipECVDI

**IMAGING
PERFORMED BY**

Mobile Pet Imaging

HOSPITAL NAME

Mobile Pet Imaging

REFERRING VET

Novoa

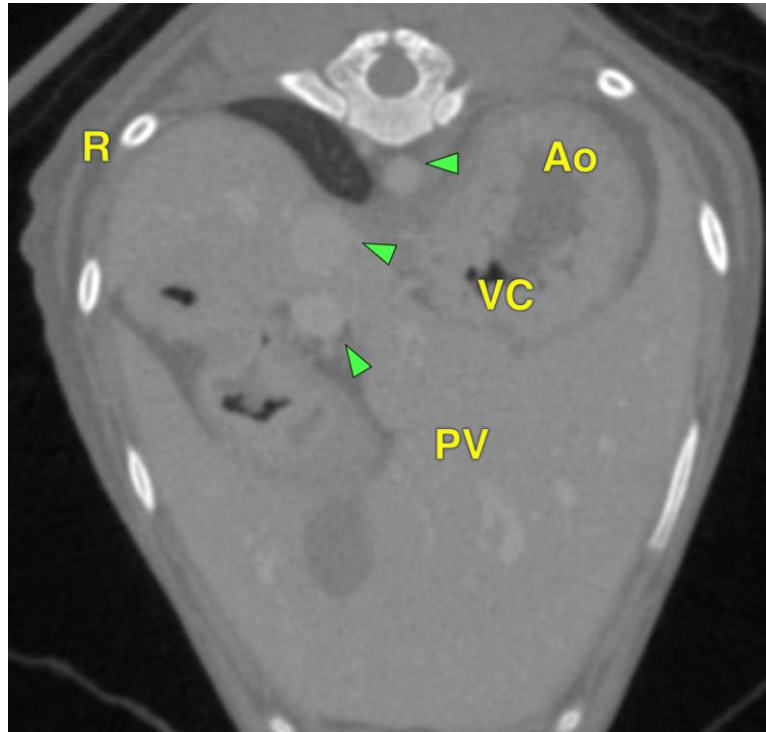
INVOICE

73899

DATE

2-23-26

effusion. The intensity of the post procedural patient monitoring needs to be tailored to the degree of deviation from normal reference ranges.



The information and recommendations provided are based on the images presented by the referring veterinarian. No evaluation can be communicated regarding pathology that was not visible in the image/video clips provided.

Thank you for this referral. If the clinical or image interpretation does not parallel your findings or if I can be of any further assistance please contact me.

Nele Eley (Ondreka), DVM, Dr. med. vet., DipECVDI
European Specialist in Veterinary Diagnostic Imaging, Cert. Radiology,
Senior lecturer University of Giessen/Germany, Veterinary Faculty, Department of Radiology.
info@sonopath.com