



## PATIENT

Diesel #32555B-CT  
Brunning

## SPECIES

Canine

## BREED

Husky

## SEX

MN

## AGE

9Y, 7M

## WEIGHT

86lbs

## INTERPRETED BY

Nele Eley (Ondreka),  
DVM Dr. med. vet.,  
DipECVDI

## IMAGING PERFORMED BY

Angie Werth, LVT

## HOSPITAL NAME

Gentle Doctor Animal  
Hospitals

## REFERRING VET

Sarah Rotthaus, DVM

## INVOICE

73883

## DATE

2-23-26

## PRESENTING CLINICAL SIGNS

Diesel has a 6 week history of left forelimb lameness and severe pain when moving neck to the left. Diesel responds to steroids but not completely. Prednisone was tapered off after side effects became unmanageable. Carprofen was not helpful. He is currently on robaxin 1000mg BID and gabapentin 300mg TID. CBC/Chem within normal limits.

## COMPUTED TOMOGRAPHIC STUDY OF THE CERVICAL SPINE

Plain and post-IV contrast studies are available for review.

## COMPUTED TOMOGRAPHIC FINDINGS

C2/3 vertebrae present fusion of their vertebral bodies and arches. No direct spinal cord compression, signs of instability, or stenosis are observed. The fusion may serve as biomechanical fulcrum potentially contributing to stress at adjacent segments, in particular C3/4.

Mild narrowing of the intervertebral disc space C6/7 is noted with moderate disc herniation predominantly left sided and asymmetric. The herniation appears to impinge on the left C6/7 nerve root. Morphology suggests a more chronic protrusion lesion rather than acute extrusion.

No other cervical vertebral malformations or acute fractures are identified.

The adjacent soft tissues are otherwise unremarkable.

## COMPUTED TOMOGRAPHIC DIAGNOSIS

- Chronic left sided C6/7 disc protrusion with suspect nerve root compression.
- C2/3 vertebral fusion – incidental.

## INTERPRETATION OF FINDINGS & FURTHER RECOMMENDATIONS

The CT study demonstrates a chronic left sided C6/7 disc protrusion with nerve root compression likely accounting for the left forelimb lameness and pain.

The C2/3 vertebral fusion is an incidental congenital or developmental abnormality but may predispose to biomechanical stress at adjacent cervical segments.

MRI of the cervical spine is recommended to further evaluate the spinal cord, nerve roots, and disc material prior to any surgical planning. Consider continued medical management and analgesia as clinically indicated.



## PATIENT

Diesel #32555B-CT  
Brunning

## SPECIES

Canine

## BREED

Husky

## SEX

MN

## AGE

9Y, 7M

## WEIGHT

86lbs

## INTERPRETED BY

Nele Eley (Ondreka),  
DVM Dr. med. vet.,  
DipECVDI

## IMAGING PERFORMED BY

Angie Werth, LVT

## HOSPITAL NAME

Gentle Doctor Animal  
Hospitals

## REFERRING VET

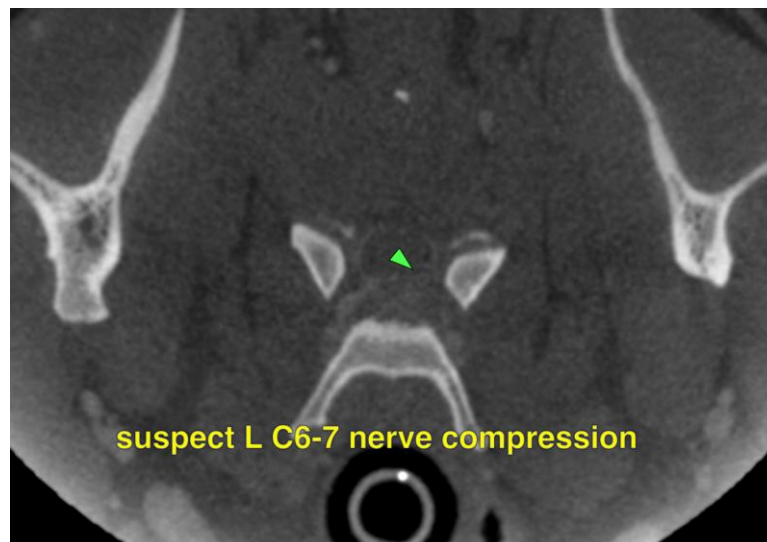
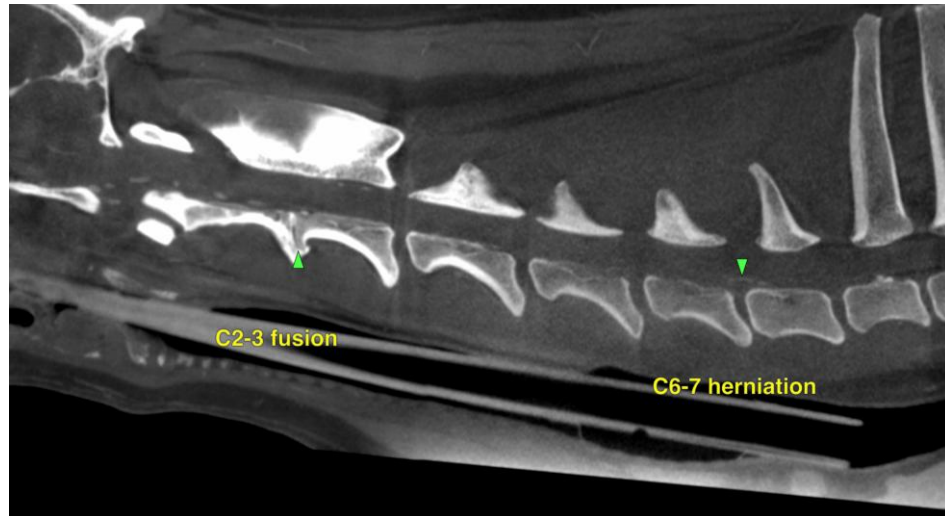
Sarah Rotthaus, DVM

## INVOICE

73883

## DATE

2-23-26



The information and recommendations provided are based on the images presented by the referring veterinarian. No evaluation can be communicated regarding pathology that was not visible in the image/video clips provided.

Thank you for this referral. If the clinical or image interpretation does not parallel your findings or if I can be of any further assistance please contact me.

Nele Eley (Ondreka), DVM, Dr. med. vet., DipECVDI  
European Specialist in Veterinary Diagnostic Imaging, Cert. Radiology,  
Senior lecturer University of Giessen/Germany, Veterinary Faculty, Department of Radiology.  
[info@sonopath.com](mailto:info@sonopath.com)