



PATIENT

Gus Walrath

PRESENTING CLINICAL SIGNS

RTL lameness x 60 days worsening Sore ROM shoulder and biceps stretch Known bilateral hip dysplasia with weakness US: shoulders R/O compensatory strain Active young Rottweiler Abnormal PE/Chem/CBC/UA Results: Normal joint taps Normal radiographs of all TL joints bilaterally - shoulders, elbow, carpi

SPECIES

Canine

ULTRASONOGRAPHIC FINDINGS

Right Shoulder

BREED

Rottweiler

The supraspinatus, deltoideus and infraspinatus muscles present within normal limits for shape, volume, echoarchitecture and echogenicity. The transition to the supraspinatus tendon is even and thin.

SEX

Male Intact

The supraspinatus thickness measures 10mm. Moderate internal echoarchitectural remodeling and relative hyperechogenicity of the supraspinatus tendon are seen. Several partially and fully shadowing echogenic foci of up to 1.5mm diameter are seen within the supraspinatus tendon. The supraspinatus tendon is relatively large which is typical in Rottweilers and in close anatomic relationship to the biceps tendon. However, no direct impingement is seen. The attachment to the bone surface of the greater humeral tubercle is even and smooth.

AGE

3

The infraspinatus muscle condenses and narrows down to a long tendon of even width, smooth outline and regular echogenic fibular echoarchitecture and up to the attachment to the bone surface of the humerus. There is no evidence of enlargement of the infraspinatus bursa.

INTERPRETED BY

Nele Eley, DVM
Dr. med. Vet. DipECVDI

The biceps tendon can be seen from its origin through the bicipital groove, up to the musculotendinous transition and is within normal limits for shape, echogenicity and echoarchitecture. There is no evidence of synovial thickening and no evidence of abnormal effusion. The bone surface of the bicipital groove is even and smooth.

HOSPITAL NAME

Animal Care Center
of Castle Pines

The visible margins of the shoulder joint are within normal limits.

Left Shoulder

The supraspinatus, deltoideus and infraspinatus muscles present within normal limits for shape, volume, echoarchitecture and echogenicity. The transition to the supraspinatus tendon is even and thin.

REFERRING VET

Bartling

The supraspinatus thickness measures 10mm. Moderate internal echoarchitectural remodeling and relative hyperechogenicity of the supraspinatus tendon are seen. Several partially and fully shadowing echogenic foci of up to 1.5mm diameter are seen within the supraspinatus tendon. The supraspinatus tendon is relatively large which is typical in Rottweilers and in close anatomic relationship to the biceps tendon. However, no direct impingement is seen. The attachment to the bone surface of the greater humeral tubercle is even and smooth.

INVOICE

50505

The infraspinatus muscle condenses and narrows down to a long tendon of even width, smooth outline and regular echogenic fibular echoarchitecture and up to the attachment to the bone surface of the humerus. There is no evidence of enlargement of the infraspinatus bursa.

DATE

2-23-22



PATIENT

Gus Walrath

The biceps tendon can be seen from its origin through the bicipital groove, up to the musculotendinous transition and is within normal limits for shape, echogenicity and echoarchitecture. There is no evidence of synovial thickening and no evidence of abnormal effusion. The bone surface of the bicipital groove is even and smooth.

SPECIES

Canine

The visible margins of the shoulder joint are within normal limits.

BREED

Rottweiler

ULTRASONOGRAPHIC DIAGNOSIS

- Bilateral mineralizing supraspinatus tendinopathy without evidence of concurrent biceps tenosynovitis.

SEX

Male Intact

INTERPRETATION OF THE FINDINGS & FURTHER RECOMMENDATIONS

The ultrasonographic study reveals mineralizing supraspinatus tendinopathy in both shoulders. This is a typical representation of mineralizing supraspinatus tendinopathy in the Rottweiler. Clinical significance is highly variable in this patient. No direct biceps impingement and no signs of biceps tenosynovitis are seen despite the echoarchitectural changes and relatively large volume of the supraspinatus tendons at this point.

AGE

3

INTERPRETED BY

Nele Eley, DVM
Dr. med. Vet. DipECVDI

HOSPITAL NAME

Animal Care Center
of Castle Pines

REFERRING VET

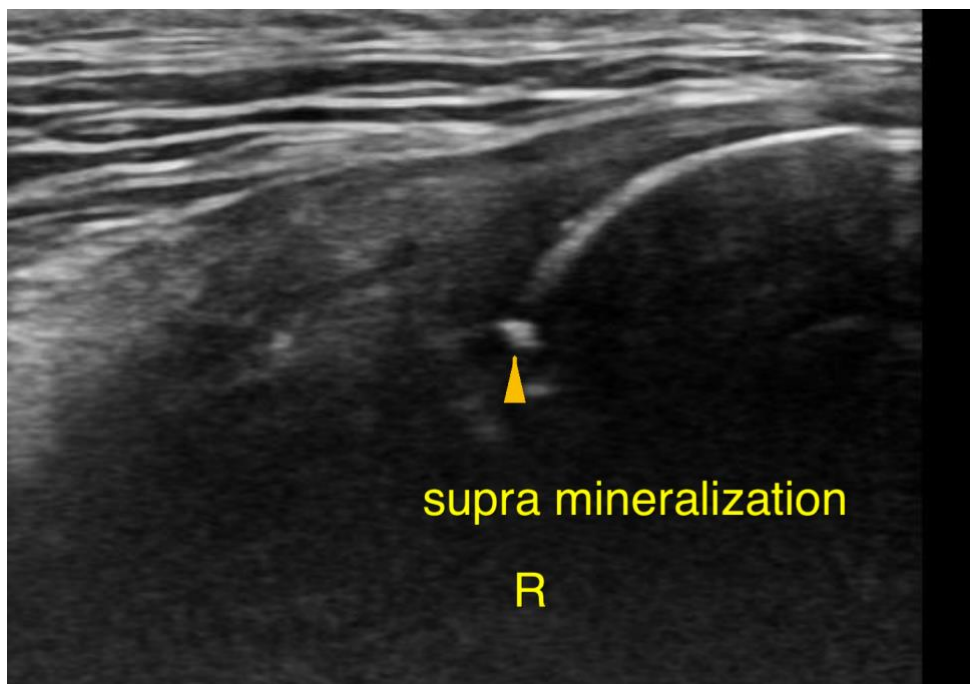
Bartling

INVOICE

50505

DATE

2-23-22





PATIENT

Gus Walrath

The information and recommendations provided are based on the images presented by the referring veterinarian/sonographer. No evaluation can be communicated regarding pathology that was not visible in the image/video clips provided.

Thank you for this referral. If the clinical or image interpretation does not parallel your findings or if I can be of any further assistance please contact me.

SPECIES

Canine

Nele Eley, DVM, Dr. med. vet., DipECVDI
European Specialist in Veterinary Diagnostic Imaging, Cert. Radiology,
Senior lecturer University of Giessen, Germany, Veterinary Faculty, Department of Radiology
Nele.Eley@sonopath.com

BREED

Rottweiler

SEX

Male Intact

AGE

3

INTERPRETED BY

Nele Eley, DVM
Dr. med. Vet. DipECVDI

HOSPITAL NAME

Animal Care Center
of Castle Pines

REFERRING VET

Bartling

INVOICE

50505

DATE

2-23-22