

**PATIENT**

Grizzly Zygiel

PRESENTING CLINICAL SIGNS

Coughing after drinking water.. No murmur ausculted..

SPECIES

Canine

RADIOGRAPHIC STUDY OF THE THORAX

Single right lateral view available for review.

BREED

Pomeranian

RADIOGRAPHIC FINDINGS

Undulation of the caudal cervical tracheal wall and moderate caudal cervical as well as thoracic tracheal collapse are seen.

SEX

Male Neutered

The degree of pulmonary inflation is fair. A moderate generalized bronchointerstitial lung pattern appears to be present.

The lobar bronchi appear to be partially collapsed.

AGE

12 Years

The view is mildly rotated which may enhance the impression of square shaped cardiac silhouette and tracheal elevation. However, the vertebral heart score appears to be mildly enlarged at 11 as well. The caudal cardiac waist is not clearly seen.

Moderate gastric aerophagia is present and indicates dyspnea.

INTERPRETED BYNele Eley, DVM
Dr. med. Vet. DipECVDI**RADIOGRAPHIC DIAGNOSIS**

- Dynamic tracheal disease.
- Suspect concurrent bronchial collapse.
- Mild and presumably left sided cardiomegaly.
- Age related lung pattern versus chronic lower airway disease.

HOSPITAL NAMENew Bridge
Veterinary Practice**INTERPRETATION OF THE FINDINGS & FURTHER RECOMMENDATIONS**

The radiographic study clearly reveals a collapsing trachea which appears to correlate well with the clinical history of the patient. There also is evidence of mild left sided cardiomegaly. The impression, however, may be enhanced by the positioning. No evidence of cardiogenic pulmonary edema is seen. Further definition would only be indicated in case of pertinent clinical signs or auscultation of a murmur.

REFERRING VET

Dr. Abina Glennon

The impression of increased bronchopulmonary opacity is likely enhanced by the low degree of pulmonary inflation. The pattern may simply reflect age related insignificant changes, however, chronic lower airway disease cannot be ruled out entirely and the concurrent presence of bronchomalacia with bronchial collapse appears likely. Consider further definition by means of airway endoscopy with airway sampling.

INVOICE

50509

DATE

2-23-22



PATIENT

Grizzly Zygiel

SPECIES

Canine

BREED

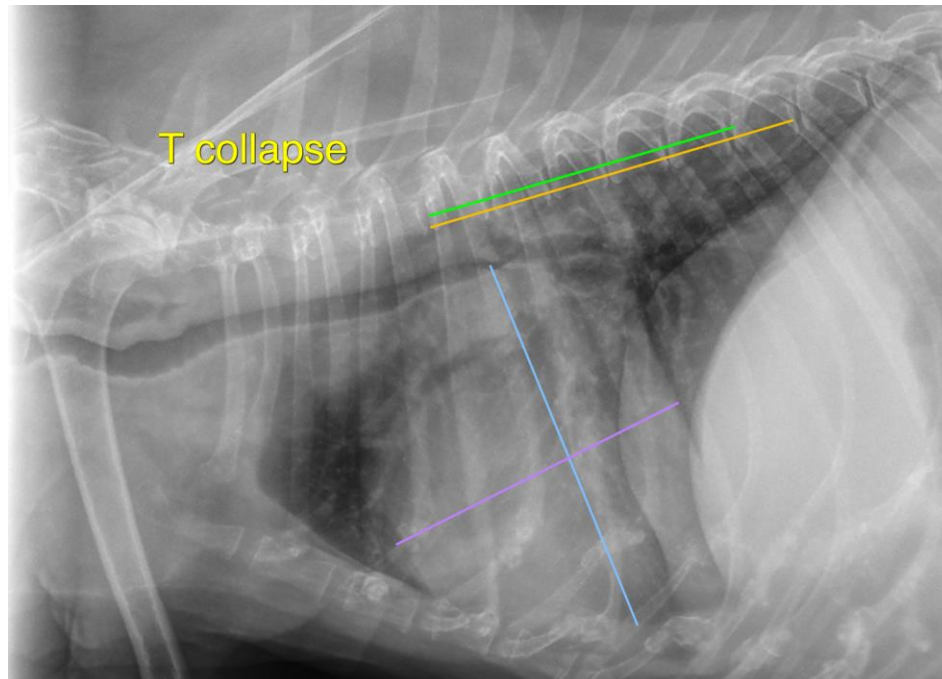
Pomeranian

SEX

Male Neutered

AGE

12 Years



INTERPRETED BY

Nele Eley, DVM
Dr. med. Vet. DipECVDI

The information and recommendations provided are based on the images presented by the referring veterinarian/sonographer. No evaluation can be communicated regarding pathology that was not visible in the image/video clips provided.

Thank you for this referral. If the clinical or image interpretation does not parallel your findings or if I can be of any further assistance please contact me.

HOSPITAL NAME

New Bridge
Veterinary Practice

Nele Eley, DVM, Dr. med. vet., DipECVDI
European Specialist in Veterinary Diagnostic Imaging, Cert. Radiology,
Senior lecturer University of Giessen, Germany, Veterinary Faculty, Department of Radiology
Nele.Eley@sonopath.com

REFERRING VET

Dr. Abina Glennon

INVOICE

50509

DATE

2-23-22