



PATIENT

Ginger Ivey

SPECIES

Canine

BREED

Poodle Mix

SEX

SF

AGE

13 Years, 2 Months

INTERPRETED BY

Nele Eley, DVM
Dr. med. Vet. DipECVDI

HOSPITAL NAME

DPC Veterinary
Hospital

REFERRING VET

Dr. White

INVOICE

50531

DATE

2-23-22

PRESENTING CLINICAL SIGNS

Rechecking: pancreatitis History: 13y 2m old SF Poodle presents for follow up of pancreatitis. Pet originally diagnosed on 2/19. No more vomiting, eating the same as usual, O feels pet is not drinking much. Concerned pet has maybe not had a BM in a few days, but not 100% sure.

Abnormal PE/Chem/CBC/UA Results: Exam Notes: Gums moist, pink, mild skin tenting; Abd soft and non-painful, no abnormalities palpated; P not tolerant of rectal exam Diagnostics & Testing: abd rads - stool throughout large colon, air filled stomach - consult pending

RADIOGRAPHIC STUDY OF THE ABDOMEN

Right lateral and ventrodorsal views totaling 2 images available for review.

RADIOGRAPHIC FINDINGS

The abdominal serosal detail appears to be mildly reduced in the cranial and mid abdomen.

There is mild generalized hepatomegaly with pointed liver margins.

The stomach is post-prandial. Moderate gastric aerophagia is noted.

Crowding of the intestine is noted within the mid abdomen.

There is a large amount of inspissated fecal matter within the colon.

RADIOGRAPHIC DIAGNOSIS

- Mildly reduced serosal detail in the cranial abdomen.
- Gastric aerophagia.
- Constipation.
- Hepatomegaly.

INTERPRETATION OF THE FINDINGS & FURTHER RECOMMENDATIONS

The reduced serosal detail may be due to regional peritonitis or regional effusion, however, it may also be secondary to crowding of the intestine in the cranial and mid abdomen.

Constipation of the colon is noted.

The gastric aerophagia may be due to abdominal pain or general excitement.

No evidence of mechanical ileus is present.

Differential diagnosis for the hepatomegaly includes metabolic/endocrine hepatopathy. Hepatitis or diffuse neoplastic infiltrate cannot be ruled out entirely but appears unlikely based on the mild radiographic changes. Correlate with laboratory values.



PATIENT

Ginger Ivey

SPECIES

Canine

BREED

Poodle Mix

SEX

SF

AGE

13 Years, 2 Months

INTERPRETED BY

Nele Eley, DVM
Dr. med. Vet. DipECVDI

HOSPITAL NAME

DPC Veterinary
Hospital

REFERRING VET

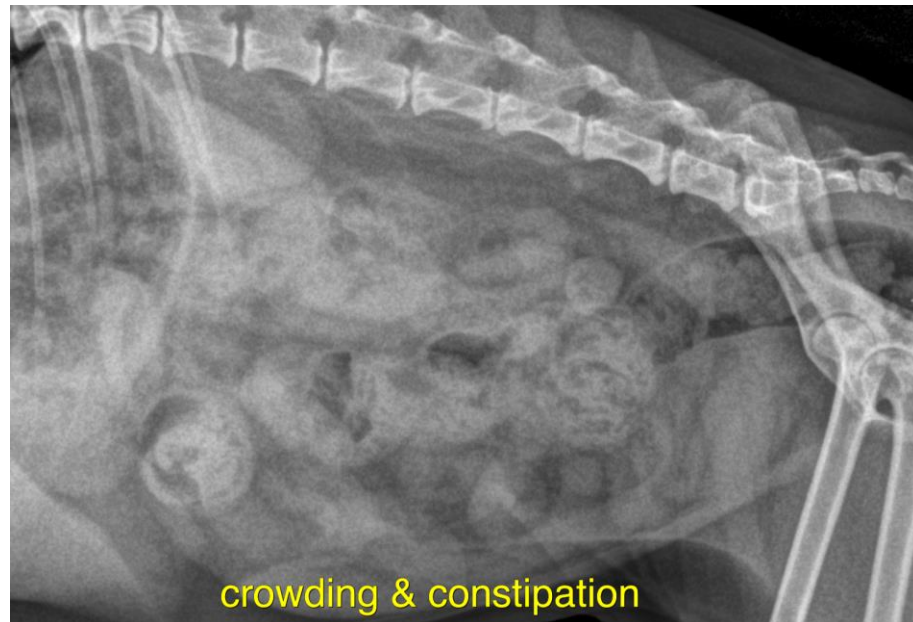
Dr. White

INVOICE

50531

DATE

2-23-22



The information and recommendations provided are based on the images presented by the referring veterinarian/sonographer. No evaluation can be communicated regarding pathology that was not visible in the image/video clips provided.

Thank you for this referral. If the clinical or image interpretation does not parallel your findings or if I can be of any further assistance please contact me.

Nele Eley, DVM, Dr. med. vet., DipECVDI
European Specialist in Veterinary Diagnostic Imaging, Cert. Radiology,
Senior lecturer University of Giessen, Germany, Veterinary Faculty, Department of Radiology
Nele.Eley@sonopath.com