

**PATIENT PRESENTING CLINICAL SIGNS**

Foxtrott Forrest Patient is snoring- never snored before

COMPUTED TOMOGRAPHIC STUDY OF THE HEAD**SPECIES**

Canine

Plain and post contrast studies available for review.

BREED

Beagle

COMPUTED TOMOGRAPHIC FINDINGS

The brain presents no deviation from normal anatomy and symmetry. The grey and white matter distinction and the neuroparenchymal attenuation are as expected. The distribution of contrast enhancement is within normal limits throughout the parenchyma and meninges. The ventricular system is non-dilated and within the limits of the expected volume and symmetry.

SEX

FS

Thin and smoothly folded conchae and turbinates with even smooth mucosal lining.

Both temporomandibular joints present congruent joint spaces with even subchondral bone surfaces and are considered within normal limits.

AGE

7 Years

Both tympanic bullae are aerated, the mucosal lining is not seen, the bony wall is smooth and thin. The external auditory meatuses present within normal limits.

The submandibular and medial retropharyngeal lymph nodes are small and elongated with a normal short-to-long-axis-ratio is < 0.5, the attenuation and contrast enhancement pattern is uniform.

INTERPRETED BY

Nele Eley (Ondreka),
DVM Dr. med. vet.,
DipECVDI

The salivary glands present within normal limits.

Triadan 201 presents a complicated crown fracture with no evidence of associated periodontal changes. The remainder of the dentition presents within age related normal limits.

COMPUTED TOMOGRAPHIC DIAGNOSIS**HOSPITAL NAME**

Mobile Pet Imaging
CFL

- Structurally normal CT study of the nasal cavities, nasal sinuses, and nasal passages.
- Complicated crown fracture Triadan 201.

INTERPRETATION OF FINDINGS & FURTHER RECOMMENDATIONS**REFERRING VET**

Borecky

The CT study reveals no evidence of abnormality in the upper airways. The nasal cavities and paranasal sinuses present within normal limits. There is no evidence of foreign material, fluid secretions, mucosal swelling, turbinate destruction, soft tissue mass, nasopharyngeal stenosis, or other potential explanation of the clinical signs. Dynamic pharyngeal collapse and other functional abnormality appears to be a potential explanation of the recent onset of snoring.

INVOICE

50518

Complementary endoscopic evaluation of the upper airways could be considered for a complete workup.

DATE

2-23-22



PATIENT

Foxtrott Forrest

SPECIES

Canine

BREED

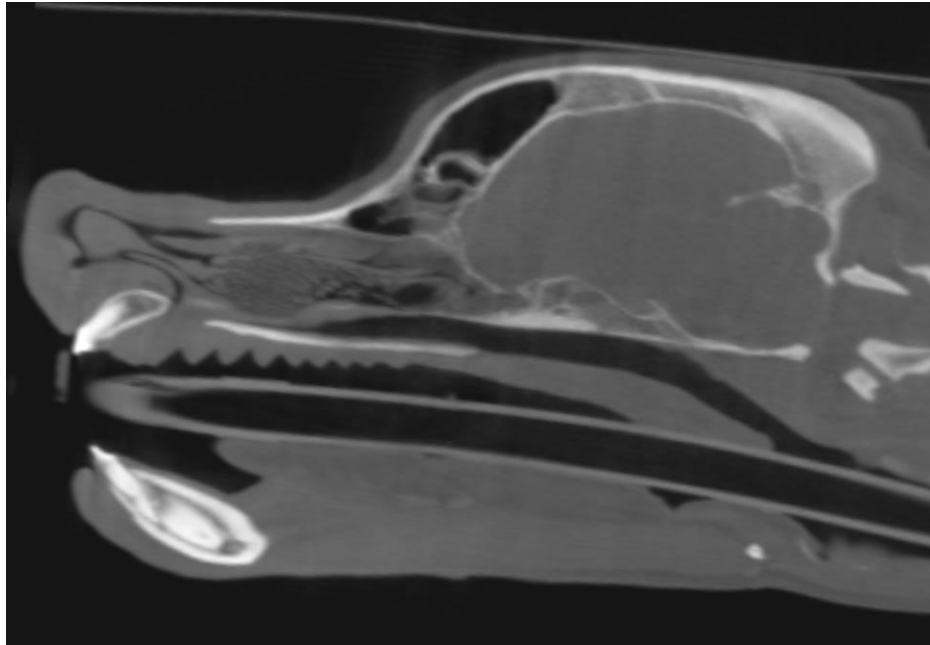
Beagle

SEX

FS

AGE

7 Years



The information and recommendations provided are based on the images presented by the referring veterinarian. No evaluation can be communicated regarding pathology that was not visible in the image/video clips provided.

INTERPRETED BY

Nele Eley (Ondreka),
DVM Dr. med. vet.,
DipECVDI

Thank you for this referral. If the clinical or image interpretation does not parallel your findings or if I can be of any further assistance please contact me.

Nele Eley (Ondreka), DVM, Dr. med. vet., DipECVDI
European Specialist in Veterinary Diagnostic Imaging, Cert. Radiology,
Senior lecturer University of Giessen/Germany, Veterinary Faculty, Department of Radiology.
Nele.Eley@sonopath.com

HOSPITAL NAME

Mobile Pet Imaging
CFL

REFERRING VET

Borecky

INVOICE

50518

DATE

2-23-22