



PATIENT PRESENTING CLINICAL SIGNS

Cesare Lizzi history of coughing frequently especially when lying down . On auscultation of heart low grade heart murmur, grade 1 -2. On physical exam, has abdominal breathing. History of panting

SPECIES RADIOGRAPHIC STUDY OF THE THORAX & ABDOMEN

Canine Multiple orthogonal views of the thorax and abdomen totaling 16 images available for review.

BREED RADIOGRAPHIC FINDINGS

Labrador Retriever

Thorax

The surrounding bony structures are within normal limits.

The extrathoracic soft tissues present homogeneous without abnormalities.

Male The vertebral heart score is 10.5. No specific chamber enlargement is noted. The pulmonary vasculature presents within normal limits.

AGE The cranial mediastinum presents the expected soft tissue opacity. The mediastinal width is less than twice the width of the vertebral column at the same level.

12 Years The trachea is normal in diameter and presents the anticipated course. The luminal outline of the trachea is smooth.

INTERPRETED BY

Nele Eley, DVM
Dr. med. Vet. DipECVDI

The lung presents a moderate generalized bronchial pattern. Occasional age related incidental pulmonary osteomas are seen.

The diaphragm is well delineated with even surface and the expected mild cranial bulging of the diaphragmatic cupola.

HOSPITAL NAME

Truscott Animal
Hospital

Abdomen

The patient is obese.

Excessive gastric aerophagia is noted.

REFERRING VET

Medhat Meawad

Moderate generalized enlargement of the prostate appears to be present with no evidence of abnormal opacities and well delineated margins. The prostatic height occupies approximately 60% of the thoracic inlet.

INVOICE

50522

No significant dorsal deviation of the descending colon is seen.

There is no evidence of sublumbar lymphadenomegaly.

Severe lumbosacral spondylosis and a lumbosacral transitional vertebra are seen.

DATE

2-23-22

The right coxofemoral joint presents mild osteoarthritic changes.

The muscle volume of the hind limbs appears to be low.



PATIENT

Cesare Lizzi

SPECIES

Canine

BREED

Labrador Retriever

SEX

Male

AGE

12 Years

INTERPRETED BY

Nele Eley, DVM
Dr. med. Vet. DipECVDI

HOSPITAL NAME

Truscott Animal
Hospital

REFERRING VET

Medhat Meawad

INVOICE

50522

DATE

2-23-22

RADIOGRAPHIC DIAGNOSIS

- No radiographic evidence of cardiomegaly or congestive heart failure.
- Generalized bronchial lung pattern - presumably within the age related normal limits.
- Aerophagia.
- Prostatomegaly in a non-neutered male.
- Degenerative lumbosacral stenosis.
- Mild right coxofemoral joint osteoarthritis.
- Obesity.

INTERPRETATION OF THE FINDINGS & FURTHER RECOMMENDATIONS

No significant structural bronchopulmonary changes and no evidence of hemodynamically significant cardiovascular pathology was identified radiographically. Course and width of the trachea were within normal limits. Lower airway disease cannot be ruled out entirely, however, the possibility of upper airway pathology including laryngeal malfunction appears to be a potential consideration in this patient.

The radiographic presentation of the prostate was typical for a non-neutered male and suggests presence of benign hyperplasia. However, prostatitis, neoplasia, and cystic prostatic disease cannot be ruled out as a differential diagnosis. Correlate with a clinical palpation and consider further workup as indicated.

The presence of degenerative lumbosacral stenosis appears to be a potential in this patient.



PATIENT

Cesare Lizzi

SPECIES

Canine

BREED

Labrador Retriever

SEX

Male

AGE

12 Years

INTERPRETED BY

Nele Eley, DVM
Dr. med. Vet. DipECVDI

HOSPITAL NAME

Truscott Animal
Hospital

REFERRING VET

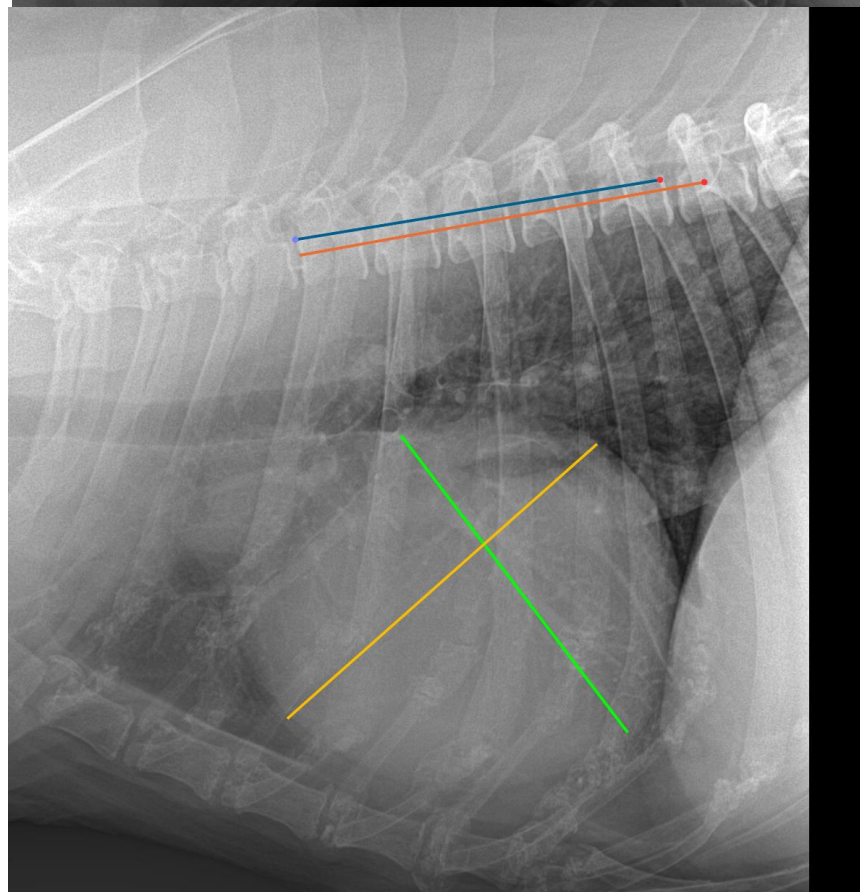
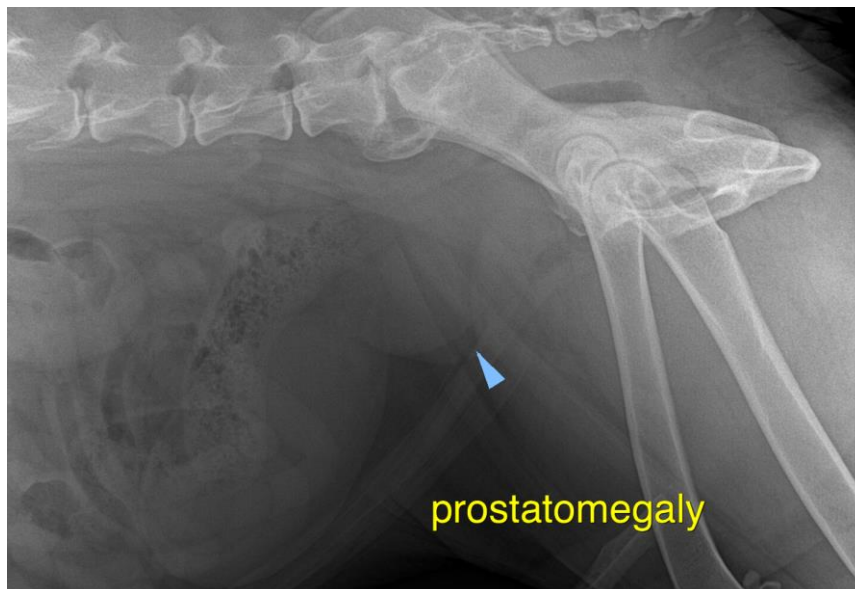
Medhat Meawad

INVOICE

50522

DATE

2-23-22





PATIENT

Cesare Lizzi

The information and recommendations provided are based on the images presented by the referring veterinarian/sonographer. No evaluation can be communicated regarding pathology that was not visible in the image/video clips provided.

Thank you for this referral. If the clinical or image interpretation does not parallel your findings or if I can be of any further assistance please contact me.

SPECIES

Canine

Nele Eley, DVM, Dr. med. vet., DipECVDI
European Specialist in Veterinary Diagnostic Imaging, Cert. Radiology,
Senior lecturer University of Giessen, Germany, Veterinary Faculty, Department of Radiology
Nele.Eley@sonopath.com

BREED

Labrador Retriever

SEX

Male

AGE

12 Years

INTERPRETED BY

Nele Eley, DVM
Dr. med. Vet. DipECVDI

HOSPITAL NAME

Truscott Animal
Hospital

REFERRING VET

Medhat Meawad

INVOICE

50522

DATE

2-23-22