

**PATIENT**

Maggie Idziszek

PRESENTING CLINICAL SIGNS

Limping and favoring left front leg. U/S of the left shoulder for further evaluation
Abnormal PE/Chem/CBC/UA Results: Xrays 1. Left shoulder: Supraspinatus tendosynovitis 2. Severe elbow arthritis bilaterally 3. Intervertebral disc disease at C6-C7 and T13-L1. 4. Possible stifle effusion (could not tell laterality from xrays)

SPECIES

Canine

ULTRASONOGRAPHIC FINDINGS**Left Shoulder**

The left supraspinatus tendon measures 9.5mm in average maximum thickness. Several up to 3.5mm sized mineralizations are seen within the supraspinatus tendon. Impingement of the biceps tendon is noted as well as moderate thickening of the bicipital synovium with moderate anechoic effusion within the biceps tendon sheath. Structural changes of the biceps tendon fibers are not seen at this point. The intertubercular groove presents mild smooth new bone formation. The infraspinatus tendon and muscle present within normal limits.

BREEDBernese Mountain
Dog**SEX**

FS

ULTRASONOGRAPHIC DIAGNOSIS

- Left mineralizing supraspinatus tendinopathy with biceps impingement and moderate biceps tenosynovitis.

AGE

8 Years, 3 Months

INTERPRETATION OF THE FINDINGS & FURTHER RECOMMENDATIONS

The ultrasonographic study reveals biceps impingement syndrome with moderate biceps tenosynovitis secondary to chronic mineralizing supraspinatus tendinopathy. Fiber disintegration of the biceps does not appear to be present at this point. Conservative management can be attempted such as with systemic NSAID administration, rest, targeted physical therapy, and a course of local prp injections into the supraspinatus tendon and shoulder joint, ideally in combination with shockwave, ultrasound, or therapeutic laser treatment.

INTERPRETED BYNele Eley, DVM
Dr. med. Vet. DipECVDI**HOSPITAL NAME**Westview Veterinary
Hospital**REFERRING VET**

Dr Brian J Barnes

INVOICE

56908

DATE

2-22-23



PATIENT

Maggie Idziszek

SPECIES

Canine

BREED

Bernese Mountain
Dog

SEX

FS

AGE

8 Years, 3 Months

INTERPRETED BY

Nele Eley, DVM
Dr. med. Vet. DipECVDI

HOSPITAL NAME

Westview Veterinary
Hospital

REFERRING VET

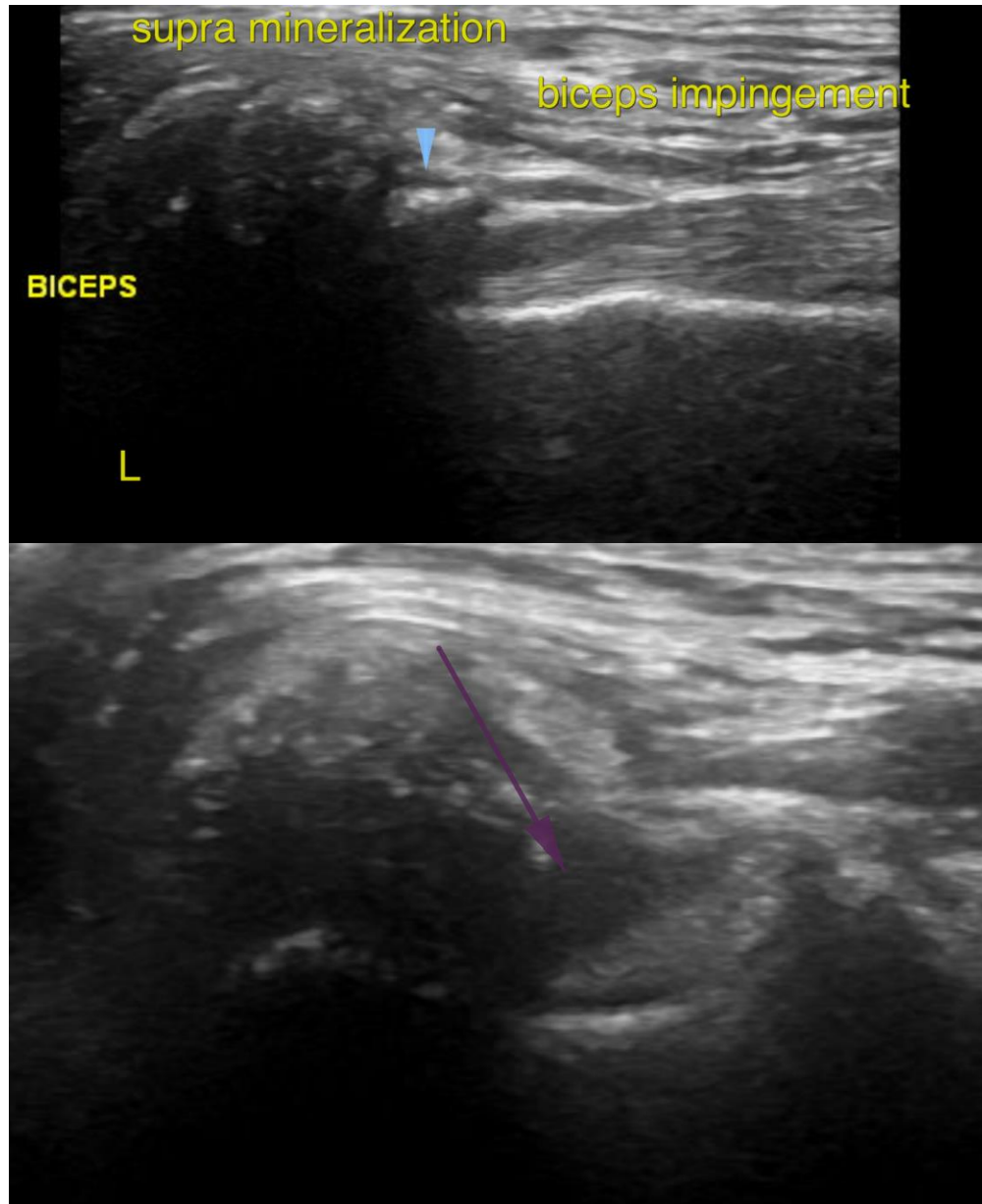
Dr Brian J Barnes

INVOICE

56908

DATE

2-22-23





PATIENT

Maggie Idziszek

The information and recommendations provided are based on the images presented by the referring veterinarian/sonographer. No evaluation can be communicated regarding pathology that was not visible in the image/video clips provided.

SPECIES

Canine

Thank you for this referral. If the clinical or image interpretation does not parallel your findings or if I can be of any further assistance please contact me.

BREED

Bernese Mountain
Dog

Nele Eley, DVM, Dr. med. vet., DipECVDI
European Specialist in Veterinary Diagnostic Imaging, Cert. Radiology,
Senior lecturer University of Giessen, Germany, Veterinary Faculty, Department of Radiology
Nele.Eley@sonopath.com

SEX

FS

AGE

8 Years, 3 Months

INTERPRETED BY

Nele Eley, DVM
Dr. med. Vet. DipECVDI

HOSPITAL NAME

Westview Veterinary
Hospital

REFERRING VET

Dr Brian J Barnes

INVOICE

56908

DATE

2-22-23