



PATIENT

Bentley Polanco

PRESENTING CLINICAL SIGNS

Diagnosed with anal sac adenocarcinoma. Grade 2 heart murmur, AUS report shows lymphadenopathy and cytology result confirmed anal sac adenocarcinoma. Need to r/o any chest or lung metastasis at this point.

SPECIES

Canine

Abnormal PE/Chem/CBC/UA Results: Results attached from cytology and AUS & echo report attached

BREED

Yorkshire Terrier

RADIOGRAPHIC STUDY OF THE THORAX

Right/left lateral and ventrodorsal views of the thorax totaling 9 images available for review.

RADIOGRAPHIC FINDINGS

The surrounding bony structures are within normal limits.

SEX

Neutered Male

The extrathoracic soft tissues present homogeneous without abnormalities.

The heart is of normal size and shape and there is no evidence of cardiac chamber or vascular enlargement. The pulmonary vasculature is within normal limits. The vertebral heart score is 9.2.

AGE

10 Years

The cranial mediastinum presents the expected soft tissue opacity. The mediastinal width is less than twice the width of the vertebral column at the same level.

INTERPRETED BY

Nele Eley, DVM
Dr. med. Vet. DipECVDI

The trachea is normal in diameter and presents the anticipated course. The luminal outline of the trachea is smooth.

The bronchial tree presents with thin walls and tapers uniformly towards the periphery as expected.

HOSPITAL NAME

Truscott Animal
Hospital

The lung parenchyma presents the expected architecture and opacity. The intrapulmonary vascular branching is seen up to the third order lung vessels. No evidence of interstitial pulmonary masses or nodules is seen.

The diaphragm is well delineated with even surface and the expected mild cranial bulging of the diaphragmatic cupola.

REFERRING VET

Dr. Medhat Meawad

RADIOGRAPHIC DIAGNOSIS

- Normal radiographic presentation of the thorax.

INTERPRETATION OF THE FINDINGS & FURTHER RECOMMENDATIONS

INVOICE

56904

The radiographic study reveals no evidence of pulmonary metastatic disease. The bronchopulmonary and cardiovascular structures present within age related normal limits.

DATE

2-22-23



PATIENT

Bentley Polanco

SPECIES

Canine

BREED

Yorkshire Terrier

SEX

Neutered Male

AGE

10 Years

INTERPRETED BY

Nele Eley, DVM
Dr. med. Vet. DipECVDI

HOSPITAL NAME

Truscott Animal
Hospital

REFERRING VET

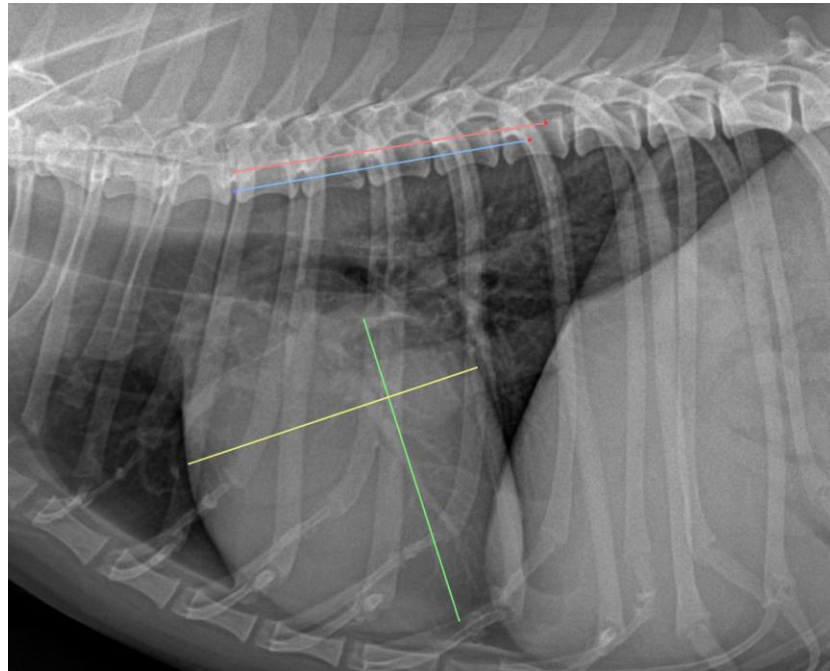
Dr. Medhat Meawad

INVOICE

56904

DATE

2-22-23



The information and recommendations provided are based on the images presented by the referring veterinarian/sonographer. No evaluation can be communicated regarding pathology that was not visible in the image/video clips provided.

Thank you for this referral. If the clinical or image interpretation does not parallel your findings or if I can be of any further assistance please contact me.

Nele Eley, DVM, Dr. med. vet., DipECVDI
European Specialist in Veterinary Diagnostic Imaging, Cert. Radiology,
Senior lecturer University of Giessen, Germany, Veterinary Faculty, Department of Radiology
Nele.Eley@sonopath.com