



**PATIENT PRESENTING CLINICAL SIGNS**

Quill Conway Limping/hopping up the stairs at home the last 6 months, primarily favoring the right front leg. Abnormal PE/Chem/CBC/UA Results: Decreased ROM and flexion of both elbows, concern for elbow dysplasia vs bone fragments in joint.

**SPECIES COMPUTED TOMOGRAPHIC STUDY OF THE ELBOWS & COXOFEMORAL JOINTS**

Canine Plain studies available for review.

**BREED COMPUTED TOMOGRAPHIC FINDINGS**

Newfoundland **Elbows**

**SEX**  
Male One approximately 5mm sized and multiple small fragments are isolated from the tip of the right medial coronoid process. There is a subchondral bone defect with peripheral sclerosis in the medial humeral condyle. Small isolated fragments are seen in the caudolateral joint compartment. There is significant articular swelling. Swelling of the flexor origin with concave defects and osseous remodeling of the medial humeral epicondyle and two flat 7mm and 4mm sized osseous structures within the flexor origin are seen.

**AGE**  
2 Years Very similar findings are present in the left elbow where a 6mm sized larger and multiple smaller fragments as well as a subchondral defect within the medial humeral condyle are noted. There also is significant articular swelling as well as swelling of the flexor origin with isolated osseous structures across from the medial humeral epicondyle.

**INTERPRETED BY**  
Nele Eley, DVM  
Dr. med. Vet. DipECVDI Both elbows present moderate osteoarthritic changes.

**Coxofemoral Joints**

Mildly reduced femoral head coverage and divergence of the joint spaces is seen bilaterally and symmetrically. At this point, there is no evidence of periarticular osteophytes.

**HOSPITAL NAME**  
Catskill Veterinary Services, PLLC Isolated ossicles of the lesser trochanter of the femur are seen in both hind limbs.

**COMPUTED TOMOGRAPHIC DIAGNOSIS**

- REFERRING VET**  
Dr. Joseph D'Abbraccio
- Bilateral medial coronoid pathology with multiple fragments and kissing lesions within the medial humeral condyles.
  - Bilateral ununited medial humeral epicondyle with associated flexor enthesopathy.
  - Bilateral secondary moderate elbow osteoarthritis.
  - Mild bilateral canine hip dysplasia with no evidence of osteoarthritic changes at this point.

**INVOICE INTERPRETATION OF THE FINDINGS & FURTHER RECOMMENDATIONS**

56870 The CT study confirms bilateral elbow dysplasia with multiple fragmentation of the medial coronoid processes. Kissing lesions are seen adjacent to the fragments within the medial humeral condyles and moderate secondary osteoarthritic changes of both elbow joints are present. There also is evidence of bilateral disturbed ossification of the medial humeral epicondyles in both elbows with ununited medial humeral epicondyles and flexor enthesopathy. Arthroscopic revision of both elbows should be considered in order to remove the fragments and prevent

**DATE**  
2-21-23



**PATIENT**

further damage to the articular structures.

Quill Conway

Note the advanced osteoarthritic changes in this patient at this very young age.

**SPECIES**

The signs of dysplasia are mild and symmetric in both hind limbs. Clinical significance is not necessarily given at this point.

Canine

**BREED**

Newfoundland

**SEX**

Male

**AGE**

2 Years

**INTERPRETED BY**

Nele Eley, DVM  
Dr. med. Vet. DipECVDI

**HOSPITAL NAME**

Catskill Veterinary  
Services, PLLC

**REFERRING VET**

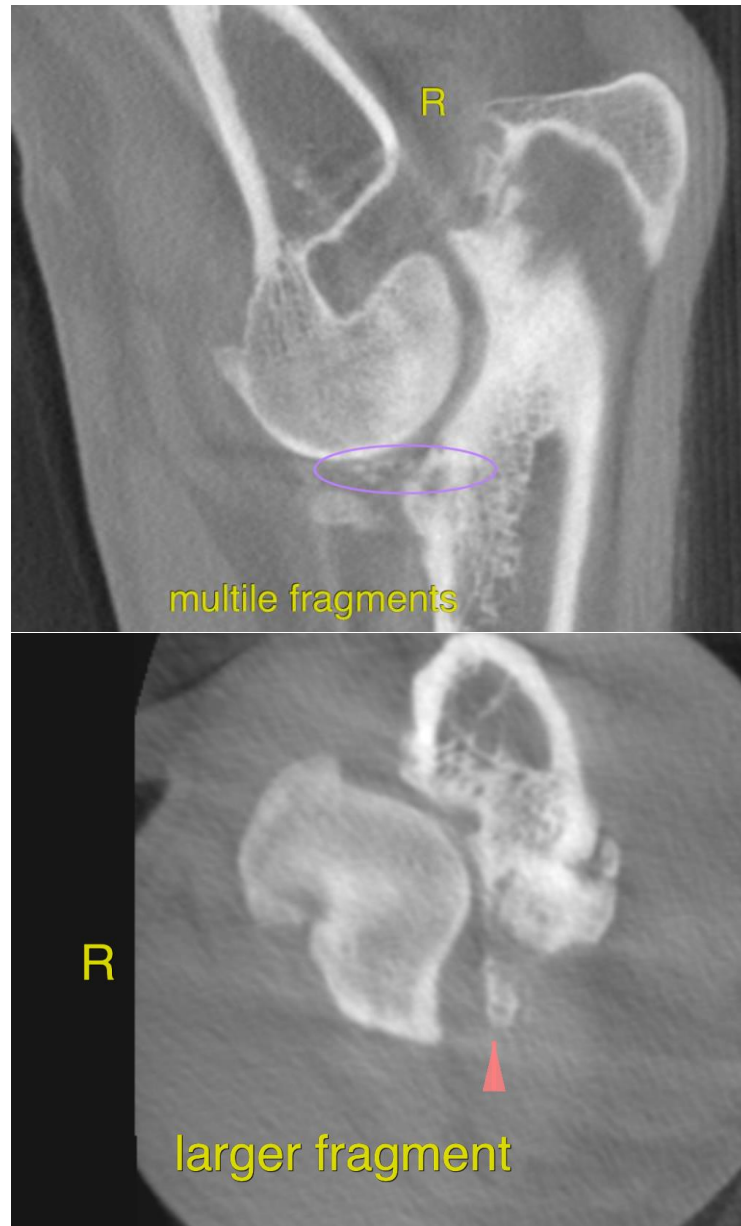
Dr. Joseph  
D'Abbraccio

**INVOICE**

56870

**DATE**

2-21-23





**PATIENT**

Quill Conway

**SPECIES**

Canine

**BREED**

Newfoundland

**SEX**

Male

**AGE**

2 Years

**INTERPRETED BY**

Nele Eley, DVM  
Dr. med. Vet. DipECVDI

**HOSPITAL NAME**

Catskill Veterinary  
Services, PLLC

**REFERRING VET**

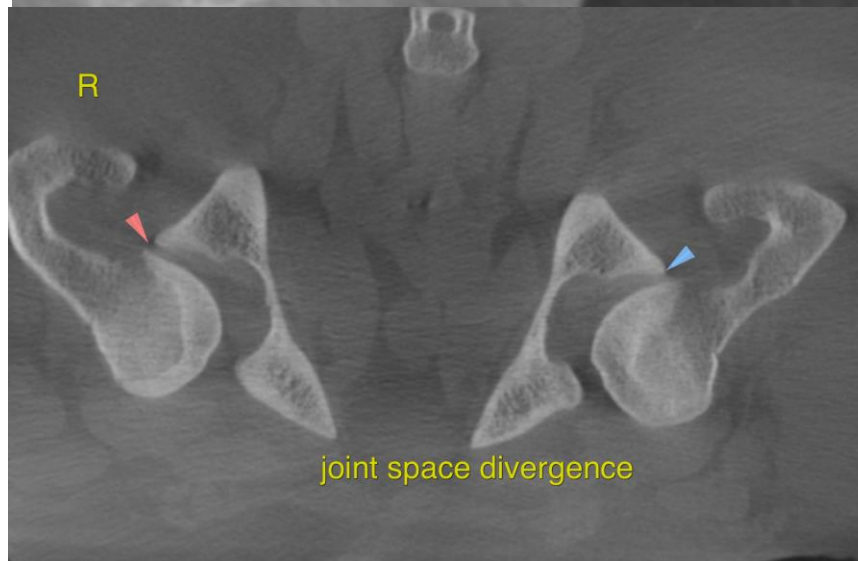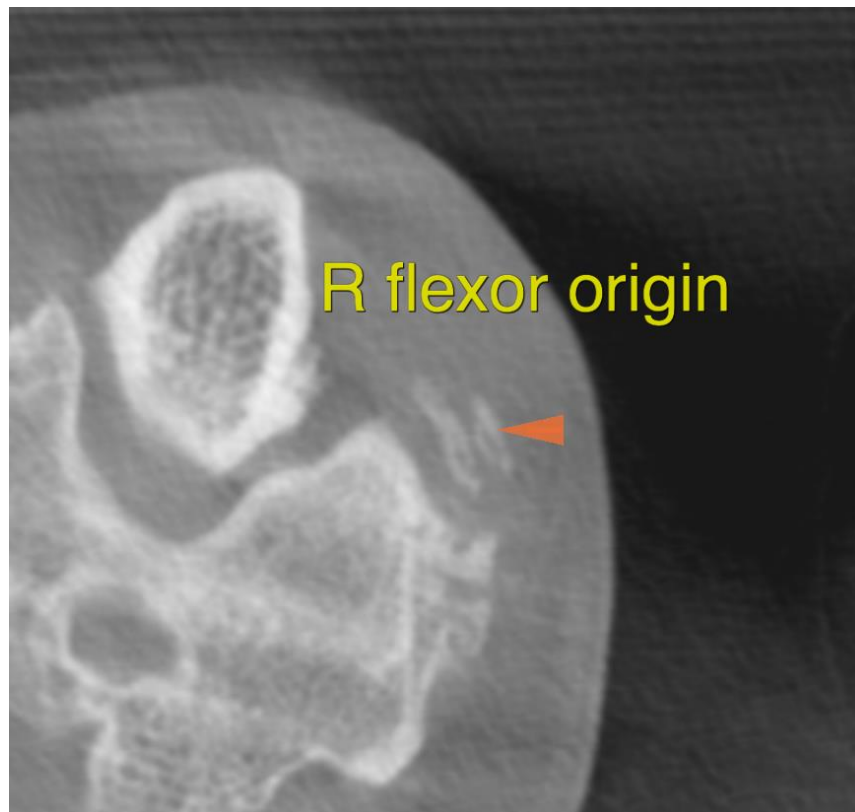
Dr. Joseph  
D'Abbraccio

**INVOICE**

56870

**DATE**

2-21-23





**PATIENT**

Quill Conway

The information and recommendations provided are based on the images presented by the referring veterinarian/sonographer. No evaluation can be communicated regarding pathology that was not visible in the image/video clips provided.

**SPECIES**

Canine

Thank you for this referral. If the clinical or image interpretation does not parallel your findings or if I can be of any further assistance please contact me.

**BREED**

Newfoundland

**Nele Eley**, DVM, Dr. med. vet., DipECVDI  
European Specialist in Veterinary Diagnostic Imaging, Cert. Radiology,  
Senior lecturer University of Giessen, Germany, Veterinary Faculty, Department of Radiology  
Nele.Eley@sonopath.com

**SEX**

Male

**AGE**

2 Years

**INTERPRETED BY**

Nele Eley, DVM  
Dr. med. Vet. DipECVDI

**HOSPITAL NAME**

Catskill Veterinary  
Services, PLLC

**REFERRING VET**

Dr. Joseph  
D'Abbraccio

**INVOICE**

56870

**DATE**

2-21-23