



PATIENT PRESENTING CLINICAL SIGNS

Nana Wu Urinary issues since birth Urine staining on back end Got infection after being born from urine scalding - rash, red itchy, - for 3-4 months After 3-4 months better but still urinary issues Dribbling a lot - daily, esp after drinking at lot Wakes up wet No meds so far Have her parents Will pee normally outside does lick back end Drinks a lot, will take it away if she drinks too much Offers water throughout the day Normal stool No v+ Sometimes brings up water if drinks a lot Just finished heat 1 day ago - first heat

SPECIES Canine

BREED Corgi

Abnormal PE/Chem/CBC/UA Results: **Previous diagnostics:** Nov 30, 2022: UA - SG 1.059, pH 7.0, 4WBC/HPF, 1 RBC/HPF, 1+ UBG, struvite crystals, rest neg/normal Jan 13, 2023: CBC - WNL [hct 52, lymph 4.3, neut 4.8, plt 108 L (clumping)] Chem - WNL, 2+ Hemolysis, [gluc 5.6, SDMA 12, creat 71, urea 8.8, ALT 44, ALP 91]

COMPUTED TOMOGRAPHIC STUDY OF THE ABDOMEN

Multiple post contrast studies in soft tissue and bone windows available for review.

SEX

F

COMPUTED TOMOGRAPHIC FINDINGS

The serosal fat presents normal attenuation behavior. There is no evidence of peritoneal effusion or peritonitis.

AGE

9 Months

Both kidneys present within normal limits for size, shape and organ architecture.

INTERPRETED BY

Nele Eley, DVM
Dr. med. Vet. DipECVDI

The right ureter is minimally dilated when compared with the left ureter. The right ureter bypasses the vesicourethral junction and can be seen paralleling the cranial pelvic urethra. Contrast media appears to be fed into the pelvic urethra directly from the right ureter. The left ureter opening appears to be level with the vesicourethral junction exactly and the jet of the left ureter is directed caudally. The urinary bladder is moderate distended at the time of examination.

HOSPITAL NAME

Animal Health
Partners

The uterus and ovaries are prominent and likely cycle related with no evidence of fluid content within the uterus.

The adrenal glands are within normal limits for size, shape and organ architecture.

Both liver and spleen present with normal shape, even surface, uniformly attenuating parenchyma and homogeneous contrast enhancement, unremarkable.

REFERRING VET

Dr. Melanie Dickinson

The pancreas is evenly contoured, the pancreatic parenchyma is homogeneous and presents uniform contrast enhancement.

INVOICE

56869

The position, delineation, wall and content of the gastrointestinal tract are considered within normal limits throughout.

The bony and surrounding soft tissue structures reveal no abnormalities.

DATE

2-21-23

COMPUTED TOMOGRAPHIC DIAGNOSIS

- Suspect bilateral ureteral ectopia with urethral leakage of contrast media.



PATIENT

Nana Wu

SPECIES

Canine

BREED

Corgi

SEX

F

AGE

9 Months

INTERPRETED BY

Nele Eley, DVM
Dr. med. Vet. DipECVDI

HOSPITAL NAME

Animal Health
Partners

REFERRING VET

Dr. Melanie Dickinson

INVOICE

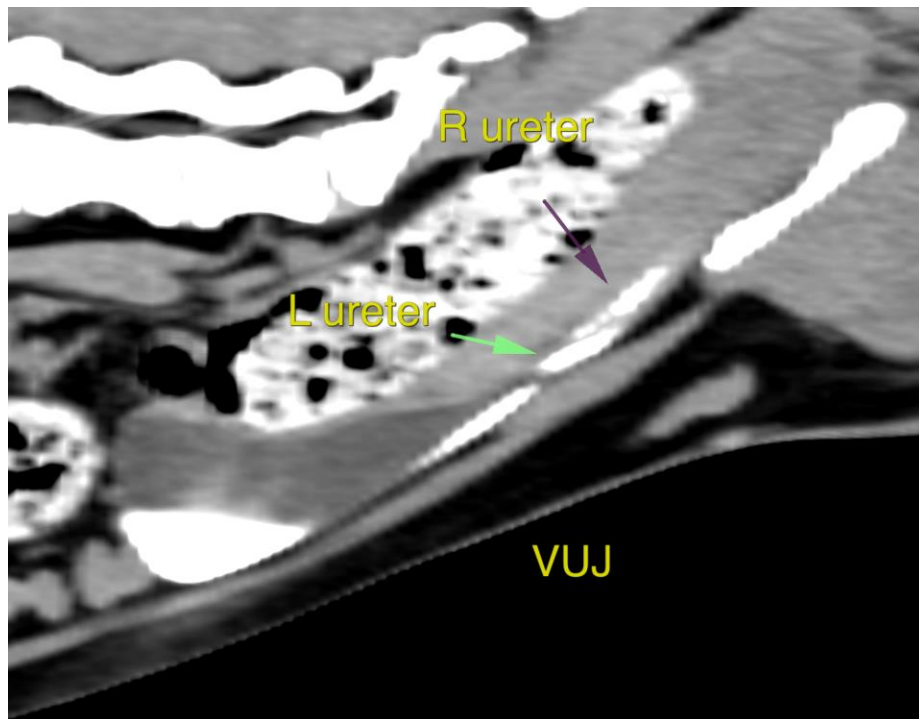
56869

DATE

2-21-23

INTERPRETATION OF THE FINDINGS & FURTHER RECOMMENDATIONS

The opening of the right ureter is definitely ectopic and caudal to the cystourethral junction. The left ureteral opening however appears to be exactly level with the cystourethral junction which strictly speaking represents ectopic as well and is likely to interfere with the continence of the patient as well. At this time, there is no significant pyelectasia and no typical CT findings that would support the presence of pyelonephritis or pyonephrosis are seen.



The information and recommendations provided are based on the images presented by the referring veterinarian/sonographer. No evaluation can be communicated regarding pathology that was not visible in the image/video clips provided.

Thank you for this referral. If the clinical or image interpretation does not parallel your findings or if I can be of any further assistance please contact me.

Nele Eley, DVM, Dr. med. vet., DipECVDI
European Specialist in Veterinary Diagnostic Imaging, Cert. Radiology,
Senior lecturer University of Giessen, Germany, Veterinary Faculty, Department of Radiology
Nele.Eley@sonopath.com