



**PATIENT**

Moose  
Guzman/Keenan

**PRESENTING CLINICAL SIGNS**

Mass effect left shoulder region: atypical mesenchymal cells on cytology

**COMPUTED TOMOGRAPHIC STUDY OF THE SHOULDERS, THORAX, & ABDOMEN**

**SPECIES**

Canine

Plain and post contrast studies available for review.

**COMPUTED TOMOGRAPHIC FINDINGS**

**Shoulders**

A well delineated ovoid soft tissue attenuating mass is seen lateral to the left scapular spine. The mass is of uniform soft tissue attenuation and presents moderate nonuniform contrast enhancement. Mild peripheral fat stranding is seen. The mass is situated approximately lateral to the mid third of the left scapular spine and measures 5 cm in length and 3 cm in diameter. No aggressive osteolytic lesions of the underlying bone is noted. There is a mild mass effect onto the underlying supra- and infra-spinatus muscles.

**BREED**

Labrador Retriever

**SEX**

MI

The axillary and cervical lymph nodes present within normal limits.

**AGE**

7 Years

**Thorax**

Mild T4/5 spondylosis deformans is noted.

The sternal, cranial mediastinal and tracheobronchial lymph nodes are small elongated with a normal short-to-long-axis-ratio is < 0.5, the attenuation and contrast enhancement pattern are uniform and considered within normal limits.

**INTERPRETED BY**

Nele Eley, DVM  
Dr. med. Vet. DipECVDI

The cardiovascular structures including the pulmonary vasculature are within normal limits.

**HOSPITAL NAME**

Animal Surgical  
Center

The bronchial tree presents with regular branching and tapers uniformly towards the periphery as expected, the bronchial walls are thin and smooth. The bronchus-to-artery ratio is within normal limits.

The lung parenchyma presents the expected architecture and attenuation behavior.

**REFERRING VET**

Banfield Levittown

Small incidental gas pockets are seen within the esophageal lumen, there is no evidence of abnormal dilation.

**Abdomen**

The serosal fat presents normal attenuation behavior. There is no evidence of peritoneal effusion or peritonitis.

**INVOICE**

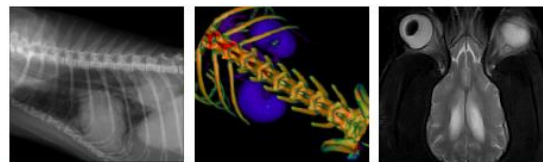
56868

Both kidneys present within normal limits for size, shape and organ architecture. After contrast administration a bilaterally symmetric and uniform nephro- and pyelogram is noted.

**DATE**

2-21-23

Moderate symmetric enlargement of the prostate measuring 4.5 x 4 x 3.5 cm is noted. Small intraparenchymal cysts are seen.



**PATIENT**

The regional lymph nodes present within normal limits.

Moose  
Guzman/Keenan

The adrenal glands are within normal limits for size, shape and organ architecture.

Both liver and spleen present with normal shape, even surface, uniformly attenuating parenchyma and homogeneous contrast enhancement, unremarkable.

**SPECIES**

Canine

The pancreas is evenly contoured, the pancreatic parenchyma is homogeneous and presents uniform contrast enhancement.

**BREED**

Labrador Retriever

The position, delineation, wall and content of the gastrointestinal tract are considered within normal limits throughout.

There is moderate degenerative lumbosacral stenosis with disc protrusion, vertebral endplate sclerosis, and spondylosis deformans.

**SEX**

MI

Both coxofemoral joints present mild osteoarthritic changes.

**AGE**

7 Years

**COMPUTED TOMOGRAPHIC DIAGNOSIS**

- Soft tissue mass lateral to the left scapular spine meeting neoplastic criteria.
- No evidence of pulmonary metastatic disease.
- No evidence of metastatic disease to the regional lymph nodes.
- Prostatomegaly compatible with benign prostatic hyperplasia of the non-neutered male.
- Degenerative lumbosacral stenosis.
- Mild bilateral coxofemoral joint osteoarthritis.
- Mild thoracic spondylosis deformans.

**INTERPRETED BY**

Nele Eley, DVM  
Dr. med. Vet. DipECVDI

**INTERPRETATION OF THE FINDINGS & FURTHER RECOMMENDATIONS**

The CT study reveals a soft tissue mass lateral to the left scapular spine meeting neoplastic criteria. Soft tissue sarcoma is considered most likely. Fibroma, round cell neoplasia, mast cell tumor, and other cannot be ruled out entirely but are thought less likely. Final diagnosis will require sampling for histology. Critical structures are not in the direct proximity of the mass. However, the mass is in direct contact with the scapular spine and underlying supra- and infra-spinatus muscles.

**HOSPITAL NAME**

Animal Surgical  
Center

**REFERRING VET**

Banfield Levittown

**INVOICE**

56868

**DATE**

2-21-23



**PATIENT**

Moose  
Guzman/Keenan

**SPECIES**

Canine

**BREED**

Labrador Retriever

**SEX**

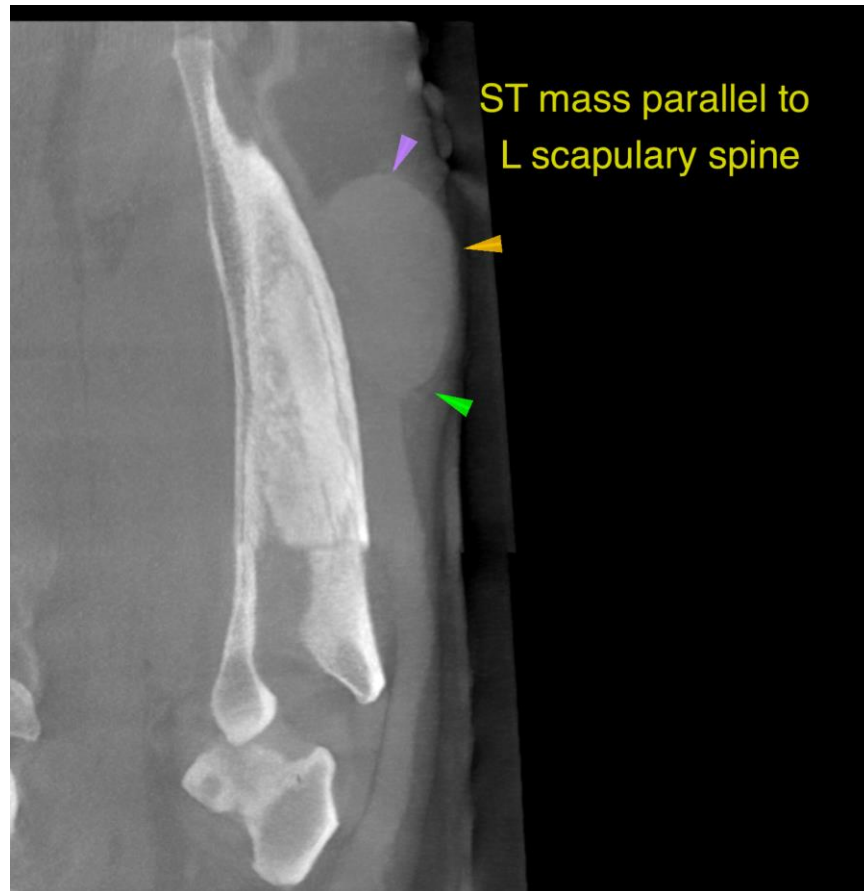
MI

**AGE**

7 Years

**INTERPRETED BY**

Nele Eley, DVM  
Dr. med. Vet. DipECVDI



**HOSPITAL NAME**

Animal Surgical  
Center

**REFERRING VET**

Banfield Levittown

**INVOICE**

56868

**DATE**

2-21-23

The information and recommendations provided are based on the images presented by the referring veterinarian/sonographer. No evaluation can be communicated regarding pathology that was not visible in the image/video clips provided.

Thank you for this referral. If the clinical or image interpretation does not parallel your findings or if I can be of any further assistance please contact me.

**Nele Eley, DVM, Dr. med. vet., DipECVDI**  
European Specialist in Veterinary Diagnostic Imaging, Cert. Radiology,  
Senior lecturer University of Giessen, Germany, Veterinary Faculty, Department of Radiology  
Nele.Eley@sonopath.com