



**PATIENT**

Lily Goodrich

**PRESENTING CLINICAL SIGNS**

RH lameness. Suspect Partial unstable CCL injury  
Abnormal PE/Chem/CBC/UA Results: N/A

**SPECIES**

Canine

**ULTRASONOGRAPHIC FINDINGS**

**Right Stifle**

Mild effusion is noted within the infrapatellar recess of the right stifle joint.

**BREED**

Lab

The cranial cruciate ligament is continuous but presents with generalized swelling and ill-defined margins. Infrapatellar fat pad heterogeneity is seen.

The suprapatellar recess and periarticular margins are not included.

**SEX**

FS

Part of the lateral meniscus is seen and in situ with smoothly delineated margins.

**AGE**

2.5 Years

**ULTRASONOGRAPHIC DIAGNOSIS**

- Cranial cruciate ligament pathology of the right stifle with articular effusion.

**INTERPRETATION OF THE FINDINGS & FURTHER RECOMMENDATIONS**

The ultrasonographic findings support early partial rupture of the right cranial cruciate ligament. Full fiber disruption is not seen, and the biomechanical stability may be partially maintained. However, it is considered likely based on the clinical history and ultrasonographic findings that the ligament is going to undergo progressive fiber disintegration.

**INTERPRETED BY**

Nele Eley, DVM  
Dr. med. Vet. DipECVDI

**HOSPITAL NAME**

Foxfield Veterinary  
Services

**REFERRING VET**

A. Rodriguez

**INVOICE**

56872

**DATE**

2-21-23



**PATIENT**

Lily Goodrich

**SPECIES**

Canine

**BREED**

Lab

**SEX**

FS

**AGE**

2.5 Years

**INTERPRETED BY**

Nele Eley, DVM  
Dr. med. Vet. DipECVDI

**HOSPITAL NAME**

Foxfield Veterinary  
Services

**REFERRING VET**

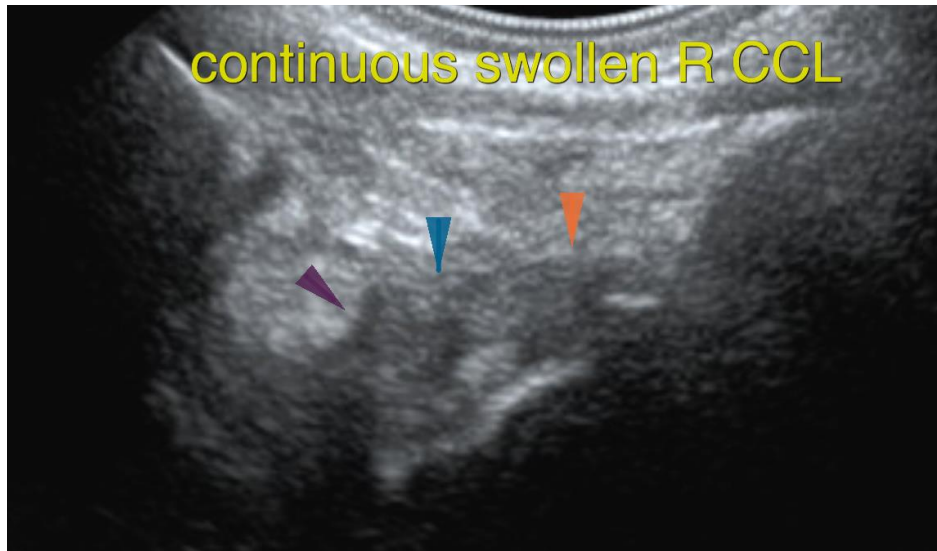
A. Rodriguez

**INVOICE**

56872

**DATE**

2-21-23



The information and recommendations provided are based on the images presented by the referring veterinarian/sonographer. No evaluation can be communicated regarding pathology that was not visible in the image/video clips provided.

Thank you for this referral. If the clinical or image interpretation does not parallel your findings or if I can be of any further assistance please contact me.

**Nele Eley**, DVM, Dr. med. vet., DipECVDI  
European Specialist in Veterinary Diagnostic Imaging, Cert. Radiology,  
Senior lecturer University of Giessen, Germany, Veterinary Faculty, Department of Radiology  
Nele.Eley@sonopath.com