



PATIENT PRESENTING CLINICAL SIGNS

Ginger Lillard
Coughing for several weeks, 24 hours of coughing up blood
Abnormal PE/Chem/CBC/UA Results: Organomegaly, poor appetite

SPECIES RADIOGRAPHIC STUDY OF THE THORAX

Canine
Left lateral and ventrodorsal views of the thorax totaling 2 images available for review.

RADIOGRAPHIC FINDINGS

BREED
Pitbull
The thoracic boundaries present within normal limits.

Course and width of the trachea are considered within normal limits.

SEX
FS
A cranioventral alveolar pattern with lobar signs of the right and left cranial lung lobes with air bronchograms are seen. The volume of the affected left and right caudal lung lobes appears to be maintained. The ventral aspect of the right middle lung lobe presents an alveolar sign too. There is no evidence of concurrent pleural effusion or mediastinal lymphadenomegaly.

AGE
The cardiac silhouette presents within normal limits. No specific chamber enlargement is noted.

11 Years
Mild gastric aerophagia is seen.

RADIOGRAPHIC DIAGNOSIS

- Bilateral lobar cranioventral alveolar lung pattern.

INTERPRETED BY

Nele Eley, DVM
Dr. med. Vet. DipECVDI

INTERPRETATION OF THE FINDINGS & FURTHER RECOMMENDATIONS

The radiographic study reveals a bilateral alveolar lobar sign of the cranial lung lobes. Differential diagnosis includes lobar pneumonia with or without vasculitis, lobar hemorrhage, and less likely lobar neoplasia. A clinical trial of treatment for infectious pneumonia could be considered. Coagulation panel should be run if not performed already in order to rule out underlying coagulopathy. Endoscopy with airway sampling and direct ultrasound guided fine needle aspiration of the lung could be considered for further definition as well. Consider narrow clinical monitoring and radiographic recheck within 48 hours depending on the clinical course of the disease since the pattern of pulmonary hemorrhage should changes significantly within this time frame.

HOSPITAL NAME

Hamburg Veterinary
Clinic

REFERRING VET

Dr. DenHeyer

INVOICE

56847

DATE

2-20-23



PATIENT

Ginger Lillard

SPECIES

Canine

BREED

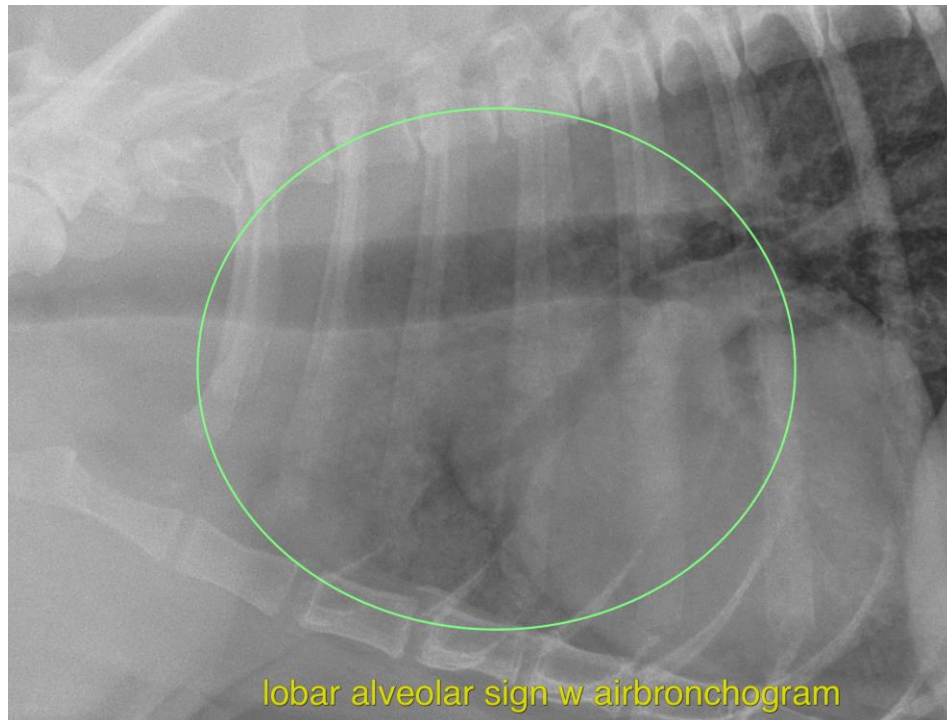
Pitbull

SEX

FS

AGE

11 Years



INTERPRETED BY

Nele Eley, DVM
Dr. med. Vet. DipECVDI

The information and recommendations provided are based on the images presented by the referring veterinarian/sonographer. No evaluation can be communicated regarding pathology that was not visible in the image/video clips provided.

Thank you for this referral. If the clinical or image interpretation does not parallel your findings or if I can be of any further assistance please contact me.

HOSPITAL NAME

Hamburg Veterinary
Clinic

Nele Eley, DVM, Dr. med. vet., DipECVDI
European Specialist in Veterinary Diagnostic Imaging, Cert. Radiology,
Senior lecturer University of Giessen, Germany, Veterinary Faculty, Department of Radiology
Nele.Eley@sonopath.com

REFERRING VET

Dr. DenHeyer

INVOICE

56847

DATE

2-20-23