



## PATIENT

Petey Dietz

## SPECIES

Canine

## BREED

Pudle Pointer Mix

## SEX

MN

## AGE

2Y, 2M

## WEIGHT

60lbs

## INTERPRETED BY

Nele Eley (Ondreka),  
DVM Dr. med. vet.,  
DipECVDI

## IMAGING PERFORMED BY

Logan/ Ralph

## HOSPITAL NAME

Animal Clinic  
Northview

## REFERRING VET

Dr. Derek Howell

## INVOICE

73564

## DATE

2-2-26

## PRESENTING CLINICAL SIGNS

Chronic, several month history of pain when opening his mouth. Seems to come and go with some times him acting completely normal and other times seeming in extreme pain. 2M Autoantibody Titers were negative for MMM. No oral masses or abnormalities appreciated.

## COMPUTED TOMOGRAPHIC STUDY OF THE HEAD

Plain and post contrast studies are available for review.

## COMPUTED TOMOGRAPHIC FINDINGS

The CT study reveals an approximately 1.5mm sized hyperattenuating foreign object in the retromolar soft tissue immediately medial and cranial to the left temporomandibular joint. Regional soft tissue swelling with contrast enhancement is present. There is focal lysis of the medial aspect of the condylar process of the left mandible/TMJ consistent with reactive changes to the foreign object. The right temporomandibular joint appears normal.

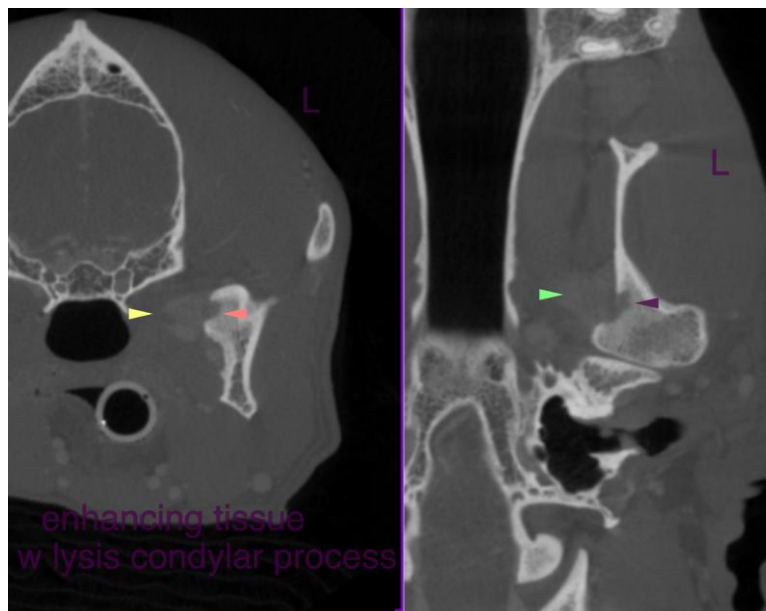
Mild regional lymphadenopathy compatible with reactive changes are seen.

## COMPUTED TOMOGRAPHIC DIAGNOSIS

- Small foreign object in the left retromolar region with reactive osteolysis of the left medial temporomandibular joint and associated regional soft tissue inflammation and lymphadenitis.

## INTERPRETATION OF FINDINGS & FURTHER RECOMMENDATIONS

The findings explain the chronic intermittent pain on mouth opening. The lytic changes in the condylar process of the left temporomandibular joint are consistent with local reactive osteolysis. Surgical removal of the foreign object is recommended to resolve local inflammation and prevent progression of the inflammation/infection. Follow up imaging may be considered to assess healing of the condylar process and rule out progressive TMJ changes.





## PATIENT

Petey Dietz

## SPECIES

Canine

## BREED

Pudle Pointer Mix

## SEX

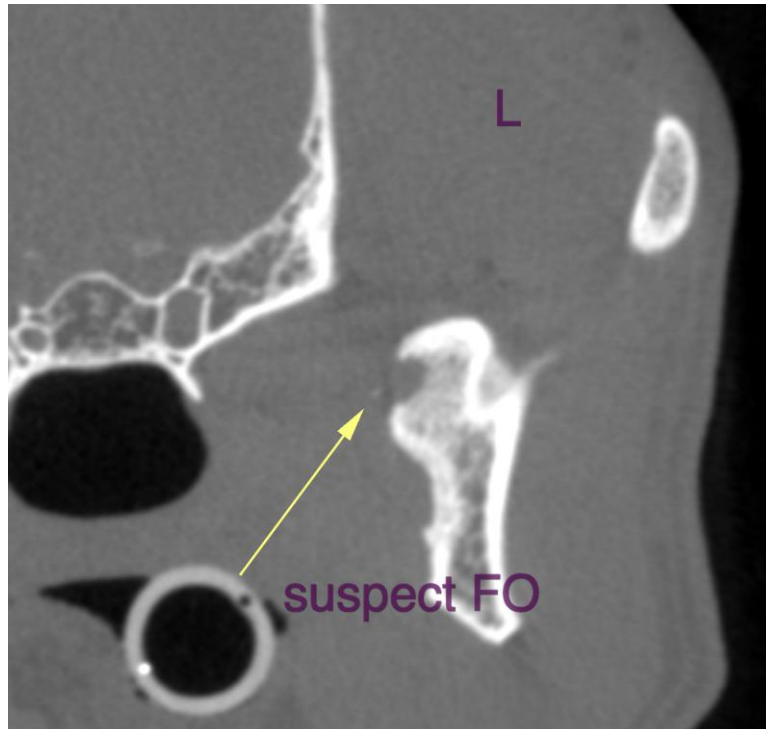
MN

## AGE

2Y, 2M

## WEIGHT

60lbs



## INTERPRETED BY

Nele Eley (Ondreka),  
DVM Dr. med. vet.,  
DipECVDI

## IMAGING PERFORMED BY

Logan/ Ralph

## HOSPITAL NAME

Animal Clinic  
Northview

## REFERRING VET

Dr. Derek Howell

## INVOICE

73564

## DATE

2-2-26

The information and recommendations provided are based on the images presented by the referring veterinarian. No evaluation can be communicated regarding pathology that was not visible in the image/video clips provided.

Thank you for this referral. If the clinical or image interpretation does not parallel your findings or if I can be of any further assistance please contact me.

**Nele Eley (Ondreka)**, DVM, Dr. med. vet., DipECVDI  
European Specialist in Veterinary Diagnostic Imaging, Cert. Radiology,  
Senior lecturer University of Giessen/Germany, Veterinary Faculty, Department of Radiology.  
[info@sonopath.com](mailto:info@sonopath.com)