



PATIENT

Harvey LaFlamme

SPECIES

Canine

BREED

Mixed

SEX

MN

AGE

13 Years, 4 Months

INTERPRETED BY

Nele Eley, DVM
Dr. med. Vet. DipECVDI

HOSPITAL NAME

Healing Spirit Animal
Wellness

REFERRING VET

Sarah Green

INVOICE

56540

DATE

2-2-23

PRESENTING CLINICAL SIGNS

SQ mass on the distal right antebrachium noted on recent exam. FNA cytology was consistent with a soft tissue sarcoma however cytology report also noted windrowing, suggestive of a viscous background. Scan performed to evaluate for communication with the carpal joint due to proximity.

Abnormal PE/Chem/CBC/UA Results: soft tissue mass on the medial aspect of the right distal antebrachium adjacent to the carpus.

COMPUTED TOMOGRAPHIC STUDY OF THE RIGHT CARPAL REGION

Plain and post contrast studies available for review.

COMPUTED TOMOGRAPHIC FINDINGS

A large spindle shaped subcutaneous mass is seen medial and palmar to the right carpal joint. The mass measures approximately 3 cm in height, 2 cm in length, and 1 cm in width. Finger-like extensions into the peripheral subcutaneous tissue are seen. The mass presents nonuniform contrast enhancement and receives several tumor feeding vessels from the medial and palmar carpal region. No evidence of osseous or articular involvement is seen.

COMPUTED TOMOGRAPHIC DIAGNOSIS

- Subcutaneous soft tissue mass meeting neoplastic criteria medial and palmar to the right carpus with no evidence of articular involvement.

INTERPRETATION OF THE FINDINGS & FURTHER RECOMMENDATIONS

The CT findings are compatible with a soft tissue neoplasia medial and palmar to the right carpus. Soft tissue sarcoma is considered by far most likely. Round cell neoplasia, mast cell tumor, and other cannot be ruled out entirely. Final diagnosis will require sampling for histology. No evidence of articular or osseous involvement is seen.



PATIENT

Harvey LaFlamme

SPECIES

Canine

BREED

Mixed

SEX

MN

AGE

13 Years, 4 Months

INTERPRETED BY

Nele Eley, DVM
Dr. med. Vet. DipECVDI

HOSPITAL NAME

Healing Spirit Animal
Wellness

REFERRING VET

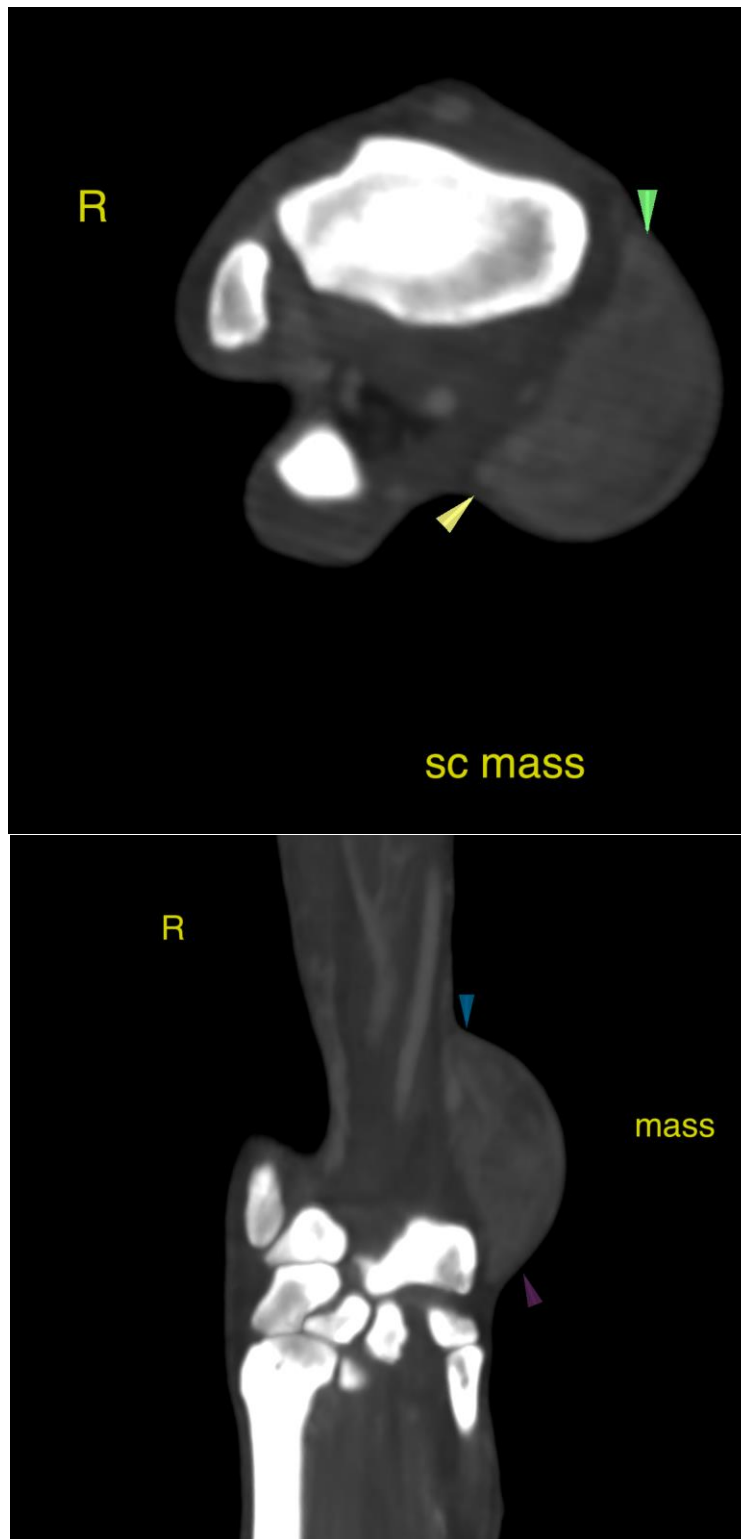
Sarah Green

INVOICE

56540

DATE

2-2-23





PATIENT

Harvey LaFlamme

The information and recommendations provided are based on the images presented by the referring veterinarian/sonographer. No evaluation can be communicated regarding pathology that was not visible in the image/video clips provided.

SPECIES

Canine

Thank you for this referral. If the clinical or image interpretation does not parallel your findings or if I can be of any further assistance please contact me.

BREED

Mixed

Nele Eley, DVM, Dr. med. vet., DipECVDI
European Specialist in Veterinary Diagnostic Imaging, Cert. Radiology,
Senior lecturer University of Giessen, Germany, Veterinary Faculty, Department of Radiology
Nele.Eley@sonopath.com

SEX

MN

AGE

13 Years, 4 Months

INTERPRETED BY

Nele Eley, DVM
Dr. med. Vet. DipECVDI

HOSPITAL NAME

Healing Spirit Animal
Wellness

REFERRING VET

Sarah Green

INVOICE

56540

DATE

2-2-23