


PATIENT PRESENTING CLINICAL SIGNS

Skye Benedek Painful palpations of cervical area and when we tried to move the neck, either to right or left or upper side the dog screamed. Occasional limp on right front leg.

SPECIES RADIOGRAPHIC STUDY OF THE CERVICAL AND THORACIC SPINE

Canine Lateral and ventrodorsal views totaling 5 images available for review.

RADIOGRAPHIC FINDINGS

BREED Mild caudal cervical tracheal collapse is noted.

Beagle There is no radiographic evidence of cranial cervical junction abnormality. The intervertebral disc space C5/6 appears to be reduced in width. No evidence of traumatic osseous injury, discospondylitis or aggressive bone lesions is seen.

SEX

Neutered Male **Please note that the patient's age in the submission form does not correlate with the radiographic presentation of the skeletal structures, which is that of a skeletally mature dog.

RADIOGRAPHIC DIAGNOSIS
AGE

- 18 Weeks
- Suspect intervertebral disc disease C5/6
 - Mild caudal cervical tracheal collapse

INTERPRETATION OF FINDINGS & FURTHER RECOMMENDATIONS

INTERPRETED BY Nele Eley (Ondreka), DVM Dr. med. vet., DipECVDI
 The radiographic findings suggest potential for intervertebral disc disease within the deep cervical spine between C5 and C6. The partial intervertebral disc space collapse may reflect uncomplicated degenerative disc disease. However, disc hernia and disc associated spinal cord compression cannot be ruled out. Other differential diagnoses would include meningitis/meningeal myelitis, vascular myelopathies and other. Depending on the clinical correlation and severity of the clinical signs, further definition by means of cross sectional imaging and ideally an MRI could be considered.

HOSPITAL NAME

Truscott AH

REFERRING VET

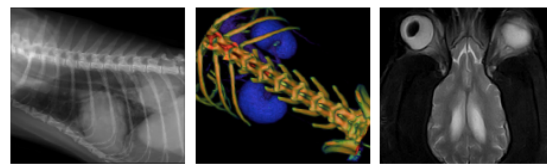
Dr. Medhat Meawad

INVOICE

35434

DATE

2/3/22



PATIENT

Skye Benedek

SPECIES

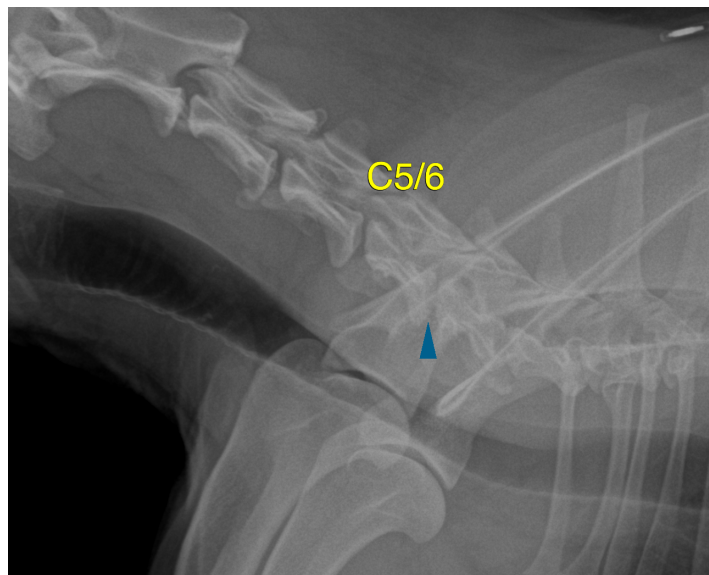
Canine

BREED

Beagle

SEX

Neutered Male



AGE

18 Weeks

The information and recommendations provided are based on the images presented by the referring veterinarian. No evaluation can be communicated regarding pathology that was not visible in the image/video clips provided.

Thank you for this referral. If the clinical or image interpretation does not parallel your findings or if I can be of any further assistance please contact me.

INTERPRETED BY

Nele Eley (Ondreka),
DVM Dr. med. vet.,
DipECVDI

Nele Eley (Ondreka), DVM, Dr. med. vet., DipECVDI
European Specialist in Veterinary Diagnostic Imaging, Cert. Radiology,
Senior lecturer University of Giessen/Germany, Veterinary Faculty, Department of Radiology.
Nele.Eley@sonopath.com

HOSPITAL NAME

Truscott AH

REFERRING VET

Dr. Medhat Meawad

INVOICE

35434

DATE

2/3/22