

**PATIENT**

Hocus Pocus Marr

**PRESENTING CLINICAL SIGNS**

Cystotomy done in September. In today for recheck xrays to make sure there are no stones.

**SPECIES**

Canine

**RADIOGRAPHIC STUDY OF THE ABDOMEN**

Lateral and ventrodorsal views of the abdomen totaling 5 images available for review. One of the right lateral views is obtained with caudal abdominal compression.

**BREED**

Papillon

**RADIOGRAPHIC FINDINGS**

The urinary bladder is moderately distended. The urinary bladder neck is not well delineated which presumably is due to the caudal position of the urinary bladder. Three faint mineral opacities appear to superimpose onto the urinary bladder which cannot be identified in the compressed view or orthogonal projections.

**SEX**

NM

**RADIOGRAPHIC DIAGNOSIS**

- Suspect urinary bladder microlithiasis and caudal position of the urinary bladder.

**AGE**

14 Years, 4 Months

**INTERPRETATION OF THE FINDINGS & FURTHER RECOMMENDATIONS**

The radiographic findings suggest potential for presence of small radiopaque urinary bladder calculi. The caudal position of the urinary bladder is typically not an issue in male dogs. Consider ultrasound in order to rule out presence of mineral concretions /small calculi within the urinary bladder in this patient. Urinalysis could be considered depending on the ultrasonographic findings as well.

**INTERPRETED BY**Nele Eley, DVM  
Dr. med. Vet. DipECVDI**HOSPITAL NAME**Elizabeth Animal  
Hospital**REFERRING VET**

Leon Anderson, DVM

**INVOICE**

50037

**DATE**

2-2-22



**PATIENT**

Hocus Pocus Marr

**SPECIES**

Canine

**BREED**

Papillon

**SEX**

NM

**AGE**

14 Years, 4 Months

**INTERPRETED BY**

Nele Eley, DVM  
Dr. med. Vet. DipECVDI

**HOSPITAL NAME**

Elizabeth Animal  
Hospital

**REFERRING VET**

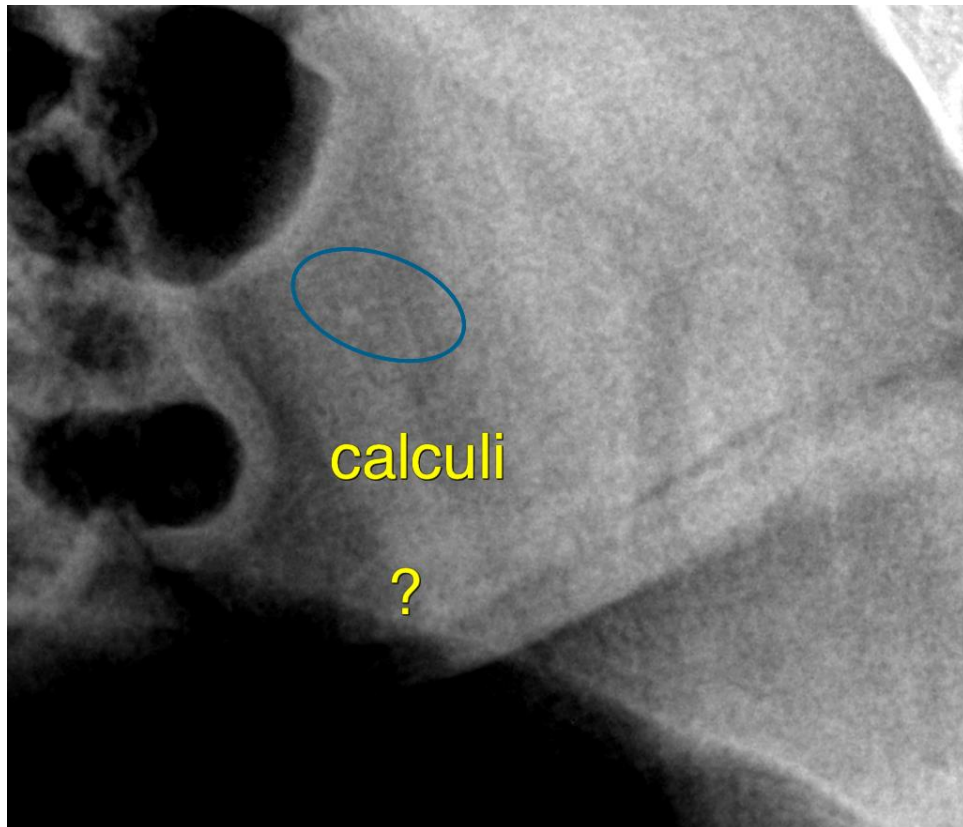
Leon Anderson, DVM

**INVOICE**

50037

**DATE**

2-2-22



The information and recommendations provided are based on the images presented by the referring veterinarian/sonographer. No evaluation can be communicated regarding pathology that was not visible in the image/video clips provided.

Thank you for this referral. If the clinical or image interpretation does not parallel your findings or if I can be of any further assistance please contact me.

**Nele Eley**, DVM, Dr. med. vet., DipECVDI  
European Specialist in Veterinary Diagnostic Imaging, Cert. Radiology,  
Senior lecturer University of Giessen, Germany, Veterinary Faculty, Department of Radiology  
Nele.Eley@sonopath.com