


PATIENT PRESENTING CLINICAL SIGNS

PATIENT Beowulf Andrus
 Beowulf presented with 7 month history of right front limb lameness. Lameness was intermittent initially but for the past 2 months it has been constant. Prednisone was dispensed and good response but limping recurred once the medication was finished. He is not on any medication currently.

SPECIES Beowulf is otherwise acting normal.

SPECIES Abnormal PE/Chem/CBC/UA Results: PE: He limps on the right front leg. Lab: Bloodwork is dated 2/2/22. CBC - PCV = 74%, WBC = 10100, neutrophils = 6340, lymphocytes = 2238, monocytes = 1240. Platelets = 164,000. Chemistry - Albumin = 1.9, Cholesterol = 424, all else normal. Urinalysis - USG = 1.025, pH = 6.5, 4+ protein, WBC = 0, RBC = 0, no bacteria, few amorphous crystals.

BREED Ultrasonographic Findings: Urinary Tract: Both kidneys are normal in size and shape. The left kidney measures 64.9 mm and the right 63.8 mm. Renal corticomedullary differentiation and echogenicity are normal. There are no renal masses or nodules. Renal pelvises are not distended. Urinary bladder walls are smooth and thin. There is no evidence of bladder stones or masses.

SEX COMPUTED TOMOGRAPHIC STUDY OF THE FRONT LIMBS, THORAX & ABDOMEN

SEX Neutered Male
 Plain studies of the front limbs from the front paws to the shoulder joints provided for review. Plain and post-contrast studies of the thorax and abdomen available

AGE COMPUTED TOMOGRAPHIC FINDINGS

AGE 6 Years
Right Shoulder
 A large amount of periarticular osteophytes is seen circumferential to the margin of the glenoid cavity and humeral head. There is moderate effusion of the right shoulder joint. A moderate semicircular exostosis is seen within the intertubercular groove of the biceps tendon.

INTERPRETED BY

Nele Eley (Ondreka),
 DVM Dr. med. vet.,
 DipECVDI

The right thoracic limb musculature is reduced in volume.

Mild deformity and heterogeneity of the medial coronoid process is seen. However, there is no evidence of fissure or fragmentation.

HOSPITAL NAME

VetMed Consultants

A mild amount of osteophytes is present at the medial contour of the medial humeral epicondyle.

Abdomen

The serosal fat presents normal attenuation behavior. There is no evidence of peritoneal effusion or peritonitis.

REFERRING VET

Dr. Mandy Lanston

Both kidneys present within normal limits for size, shape and organ architecture. After contrast administration a bilaterally symmetric and uniform nephro- and pyelogram is noted.

The adrenal glands are within normal limits for size, shape and organ architecture.

INVOICE

35436

Both liver and spleen present with normal shape, even surface, uniformly attenuating parenchyma and homogeneous contrast enhancement, unremarkable.

The pancreas is evenly contoured, the pancreatic parenchyma is homogeneous and presents uniform contrast enhancement.

DATE

2/2/22

The position, delineation, wall and content of the gastrointestinal tract are considered within normal limits throughout.



PATIENT

Beowulf Andrus

The bony and surrounding soft tissue structures reveal no abnormalities.

Thorax

The bony and surrounding soft tissue structures are within normal limits.

SPECIES

Canine

The sternal, cranial mediastinal and tracheobronchial lymph nodes are small elongated with a normal short-to-long-axis-ratio is < 0.5, the attenuation and contrast enhancement pattern is uniform and considered within normal limits.

BREED

Corgi

The cardiovascular structures including the pulmonary vasculature are within normal limits.

The bronchial tree presents with regular branching and tapers uniformly towards the periphery as expected, the bronchial walls are thin and smooth. The bronchus-to-artery ratio is within normal limits.

SEX

Neutered Male

The lung parenchyma presents the expected architecture and attenuation behavior.

Small incidental gas pockets are seen within the esophageal lumen, there is no evidence of abnormal dilation.

AGE

6 Years

COMPUTED TOMOGRAPHIC DIAGNOSIS

- Moderate chronic right shoulder arthropathy with articular effusion and osteoarthritic changes as well as intertubercular groove exostosis.
- Right medial coronoid pathology without fissure or fragmentation with minor osteoarthritic changes of the right elbow.
- Structurally normal CT studies of the thorax and abdomen
- Disuse atrophy of the right front limb musculature

INTERPRETED BY

Nele Eley (Ondreka),
DVM Dr. med. vet.,
DipECVDI

INTERPRETATION OF FINDINGS & FURTHER RECOMMENDATIONS

The main findings appear to be localized to the right shoulder. Differential diagnoses include degenerative/chronic inflammatory osteoarthritis, which can be associated with traumatic or degenerative shoulder instability syndrome, rotator cuff injury, and less likely biceps tenosynovitis. It is fairly common that an intertubercular groove exostosis develops in an osteoarthritic joint, and it is not likely that chronic biceps tendinopathy alone is the underlying cause of the changes in the other shoulder joint compartments.

HOSPITAL NAME

VetMed Consultants

REFERRING VET

Dr. Mandy Lanston

Further definition of the soft tissue structures around the shoulder by means of ultrasound or MRI could be considered, and clinical palpation for laxity, subluxation and medial instability is recommended.

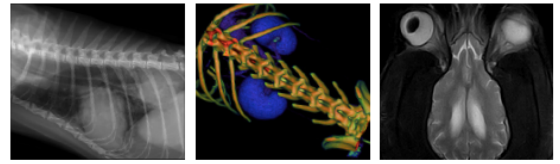
INVOICE

35436

There is evidence of medial coronoid pathology in the right elbow with minor secondary osteoarthritic changes, and no evidence of fissure or fragmentation. The changes may be associated with osteomalacia. However, clinical significance varies, especially in small and chondrodystrophic dogs.

DATE

2/2/22



PATIENT

Beowulf Andrus

SPECIES

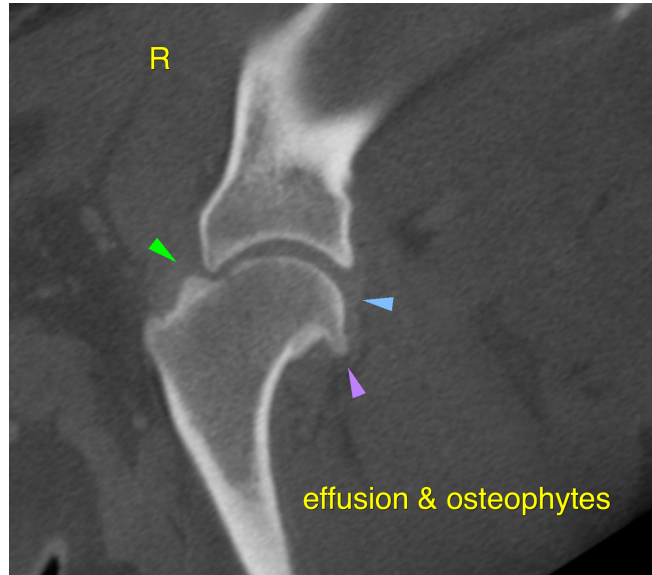
Canine

BREED

Corgi

SEX

Neutered Male



AGE

6 Years

INTERPRETED BY

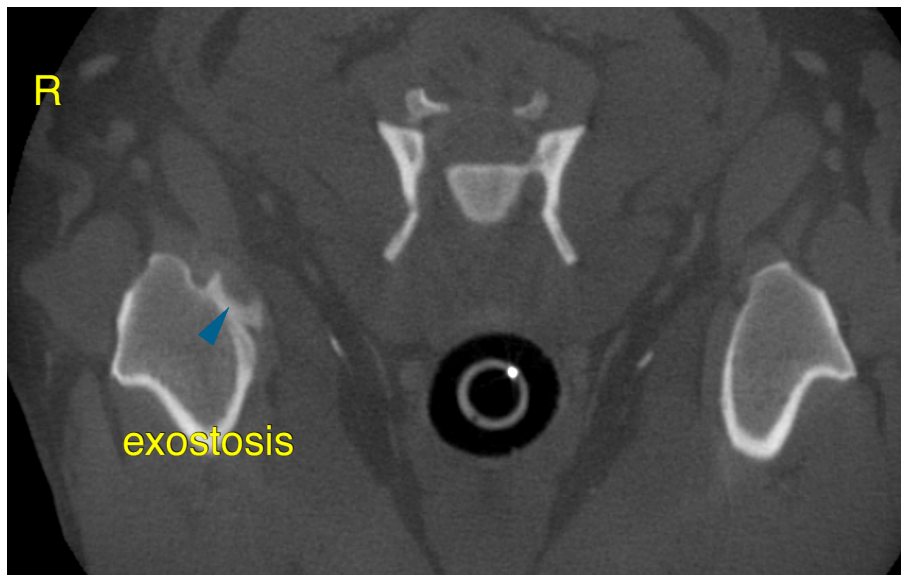
Nele Eley (Ondreka),
DVM Dr. med. vet.,
DipECVDI

HOSPITAL NAME

VetMed Consultants

REFERRING VET

Dr. Mandy Lanston

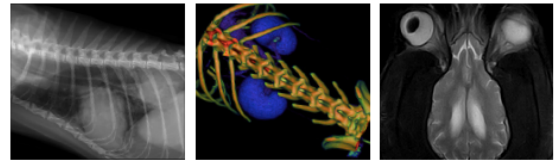


INVOICE

35436

DATE

2/2/22



PATIENT

Beowulf Andrus

SPECIES

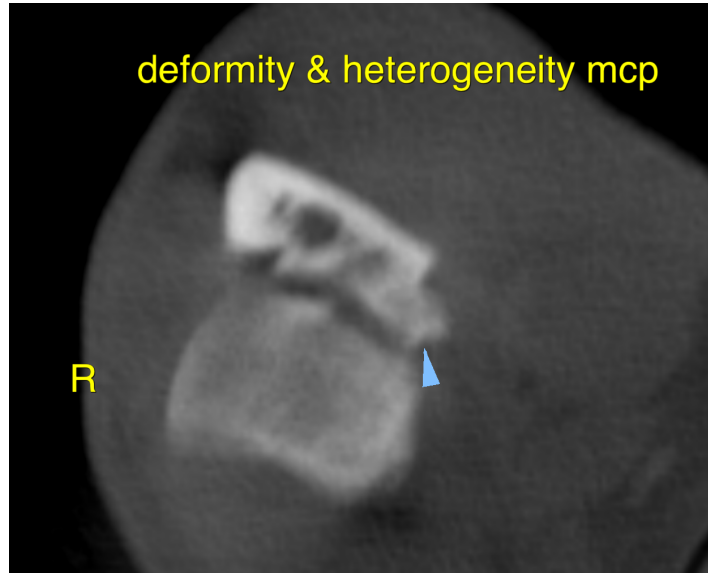
Canine

BREED

Corgi

SEX

Neutered Male



AGE

6 Years

The information and recommendations provided are based on the images presented by the referring veterinarian. No evaluation can be communicated regarding pathology that was not visible in the image/video clips provided.

Thank you for this referral. If the clinical or image interpretation does not parallel your findings or if I can be of any further assistance please contact me.

INTERPRETED BY

Nele Eley (Ondreka),
DVM Dr. med. vet.,
DipECVDI

Nele Eley (Ondreka), DVM, Dr. med. vet., DipECVDI
European Specialist in Veterinary Diagnostic Imaging, Cert. Radiology,
Senior lecturer University of Giessen/Germany, Veterinary Faculty, Department of Radiology.
Nele.Eley@sonopath.com

HOSPITAL NAME

VetMed Consultants

REFERRING VET

Dr. Mandy Lanston

INVOICE

35436

DATE

2/2/22