



PATIENT

Yuki Maradiaga

PRESENTING CLINICAL SIGNS

S: E/D/U/ NO C/S/V/D Here for follow up. O said P nose is very moist. P had diarrhea today. Vomits every a few days O: BAR, m.m-pink, CRT<2sec, EET, nose- clear wet, teeth- tartar, H/L, Abdo, U/G, skin and coat A: URI vs allergies food intolerance vs IBD vs others P: attempted Radiographs- Pet is aggressive recommended gabapentin and reschedule xrays Diag- BUN 47 CBC- WNL T4- 2.8 FPL- Normal Convenia 0.45ml SQ Adequan 0.5ml IM disp Metro 100mg/ml 1ml BID for 7 days

SPECIES

Feline

RADIOGRAPHIC STUDY OF THE THORAX & ABDOMEN

BREED

Domestic Short Hair

Lateral and ventrodorsal views of the abdomen and thorax each totaling 6 images available for review.

RADIOGRAPHIC FINDINGS

SEX

Female

Abdomen

The abdominal serosal detail is maintained.

AGE

8 Years

Differential size of the right and left kidney is noted with the right kidney measuring approximately 4.8 cm and the left measuring 3.5 cm. Irregular surface of the left kidney is noted. Mineral opacities appear to be associated with the renal diverticuli and /or renal pelvises of both kidneys.

INTERPRETED BY

Nele Eley, DVM
Dr. med. Vet. DipECVDI

There is a mineral opacity level with the vesico-trigone and urinary bladder neck seen consistently in both the right and left lateral views.

The stomach contains a mild amount of food and a moderate amount of gas.

HOSPITAL NAME

Animal Paradise
Hospital

The small intestinal loops are evenly distributed throughout the mid abdomen with a mild gas pattern. No evidence of abnormal dilation, plication, or radiopaque foreign material is seen.

A mild amount of fecal matter is seen within the descending colon.

Moderate degenerative lumbosacral stenosis is noted.

REFERRING VET

Dr. Elshafie

Thorax

The surrounding bony structures are within normal limits.

INVOICE

50424

The heart is of normal size and shape and there is no evidence of cardiac chamber or vascular enlargement. The pulmonary vasculature is within normal limits.

The cranial mediastinum presents the expected soft tissue opacity. The mediastinal width is less than twice the width of the vertebral column at the same level.

DATE

2-19-22

The trachea is normal in diameter and presents the anticipated course. The luminal outline of the trachea is smooth.

The bronchial tree presents with thin walls and tapers uniformly towards the periphery as



PATIENT expected.

Yuki Maradiaga The lung parenchyma presents the expected architecture and opacity. The intrapulmonary vascular branching is seen up to the third order lung vessels.

SPECIES The diaphragm is well delineated with even surface and the expected mild cranial bulging of the diaphragmatic cupola.

Feline

RADIOGRAPHIC DIAGNOSIS

BREED

Domestic Short Hair

- Bilateral chronic hypercalcemic nephropathy.
- Suspect urolithiasis within the lower urinary system.
- Gastric aerophagia.
- Degenerative lumbosacral stenosis.
- Radiographically normal age related thorax.

SEX

Female

INTERPRETATION OF THE FINDINGS & FURTHER RECOMMENDATIONS

AGE

8 Years

The radiographic study suggests presence of multiple multifocal urolithiasis within the urinary system including the kidneys and lower urinary tract. The findings furthermore suggest potential for chronic nephritis with end stage renal disease of the left and compensatory hypertrophy of the right kidney. Correlate with the laboratory workup and consider further definition by means of ultrasound.

INTERPRETED BY

Nele Eley, DVM
Dr. med. Vet. DipECVDI

No evidence of mechanical ileus was seen radiographically. However, further workup by means of full abdominal ultrasound including liver, pancreas, and gastrointestinal tract is recommended.

HOSPITAL NAME

Animal Paradise
Hospital

REFERRING VET

Dr. Elshafie

INVOICE

50424

DATE

2-19-22



PATIENT

Yuki Maradiaga

SPECIES

Feline

BREED

Domestic Short Hair

SEX

Female

AGE

8 Years

INTERPRETED BY

Nele Eley, DVM
Dr. med. Vet. DipECVDI

HOSPITAL NAME

Animal Paradise
Hospital

REFERRING VET

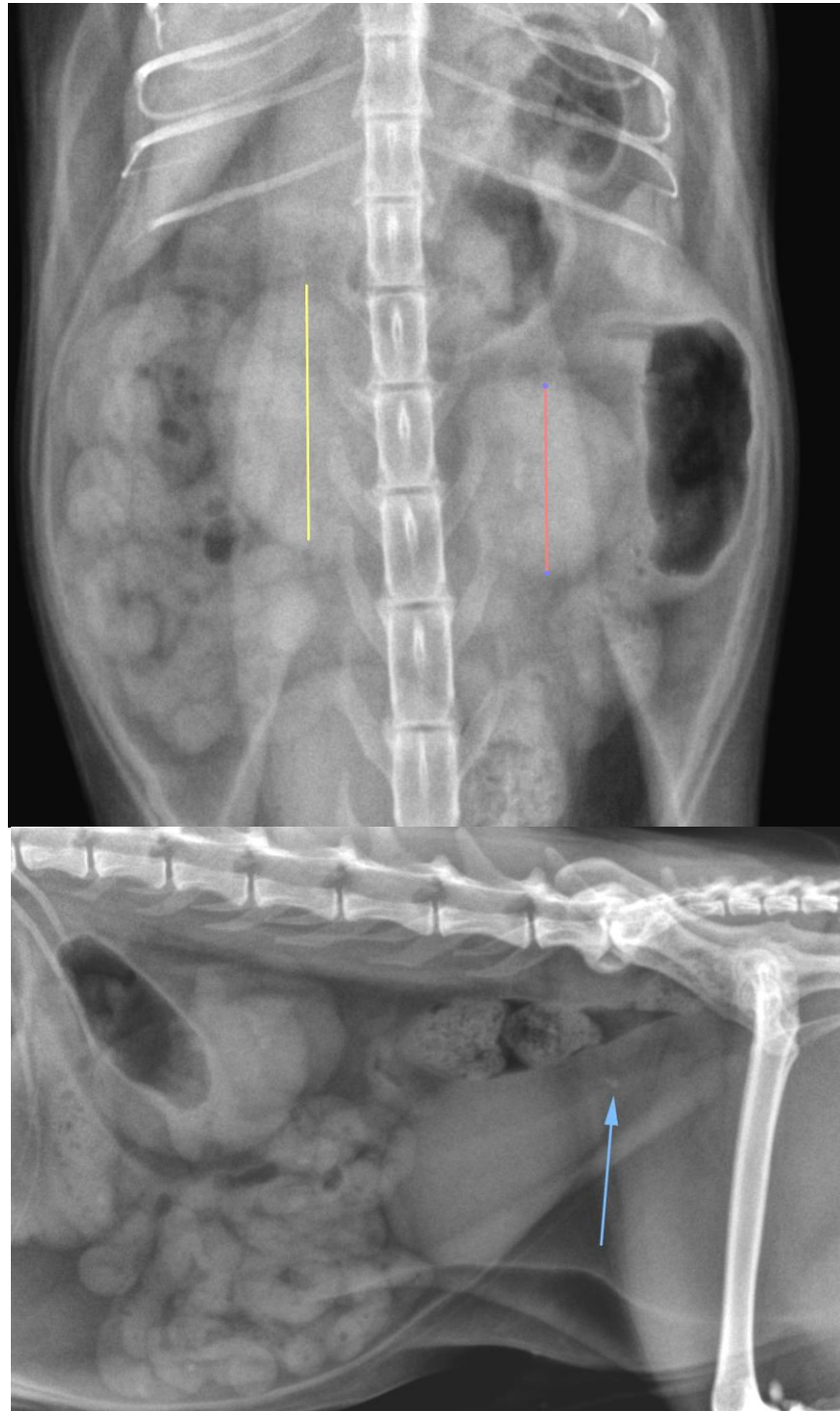
Dr. Elshafie

INVOICE

50424

DATE

2-19-22





PATIENT

Yuki Maradiaga

The information and recommendations provided are based on the images presented by the referring veterinarian/sonographer. No evaluation can be communicated regarding pathology that was not visible in the image/video clips provided.

Thank you for this referral. If the clinical or image interpretation does not parallel your findings or if I can be of any further assistance please contact me.

SPECIES

Feline

Nele Eley, DVM, Dr. med. vet., DipECVDI
European Specialist in Veterinary Diagnostic Imaging, Cert. Radiology,
Senior lecturer University of Giessen, Germany, Veterinary Faculty, Department of Radiology
Nele.Eley@sonopath.com

BREED

Domestic Short Hair

SEX

Female

AGE

8 Years

INTERPRETED BY

Nele Eley, DVM
Dr. med. Vet. DipECVDI

HOSPITAL NAME

Animal Paradise
Hospital

REFERRING VET

Dr. Elshafie

INVOICE

50424

DATE

2-19-22