



**PATIENT**

Heffalump Alboro-  
Bandalan

**PRESENTING CLINICAL SIGNS**

New patient exam. Owner has noted open-mouth breathing after playing with a new toy. Coughing is rare, approximately once per month. Abnormal PE/Chem/CBC/UA Results: Patient BAR, no significant findings on exam other than overweight.

**SPECIES**

Feline

**RADIOGRAPHIC STUDY OF THE THORAX**

Right/left lateral and ventrodorsal views of the thorax totaling 3 images available for review.

**BREED**

DSH

**RADIOGRAPHIC FINDINGS**

The degree of pulmonary inflation is moderate. A mild generalized bronchial lung pattern is noted and accentuated in the caudodorsal lung field. Regional increase in pulmonary opacity is noted in the caudal subsegment of the left cranial lung lobe.

**SEX**

No radiographic evidence of cardiovascular pathology.

MN

Course and width of the trachea are considered within normal limits. No abnormal mediastinal widening is seen.

**AGE**

11 Months

**RADIOGRAPHIC DIAGNOSIS**

- Bronchial lung pattern and suspect atelectasis of the caudal subsegment of the left cranial lung lobe.

**INTERPRETED BY**

Nele Eley, DVM  
Dr. med. Vet. DipECVDI

**INTERPRETATION OF THE FINDINGS & FURTHER RECOMMENDATIONS**

The radiographic findings are suggestive for lower airway disease with allergic lower airway syndrome being one primary differential diagnosis. The presumed atelectasis of the caudal subsegment of the left cranial lung lobe may be secondary to bronchial mucus plugging. Infectious bronchitis such as viral, bacterial, and less likely parasitic and protozoal cannot be ruled out entirely as a differential diagnosis. Consider a clinical trial of treatment for feline asthma versus further definition by means of airway sampling.

**HOSPITAL NAME**

Gentle Doctor Animal  
Hospital

**REFERRING VET**

Taylor Morrison

**INVOICE**

50415

**DATE**

2-19-22



**PATIENT**

Heffalump Alboro-Bandalan

**SPECIES**

Feline

**BREED**

DSH

**SEX**

MN

**AGE**

11 Months

**INTERPRETED BY**

Nele Eley, DVM  
Dr. med. Vet. DipECVDI

**HOSPITAL NAME**

Gentle Doctor Animal  
Hospital

**REFERRING VET**

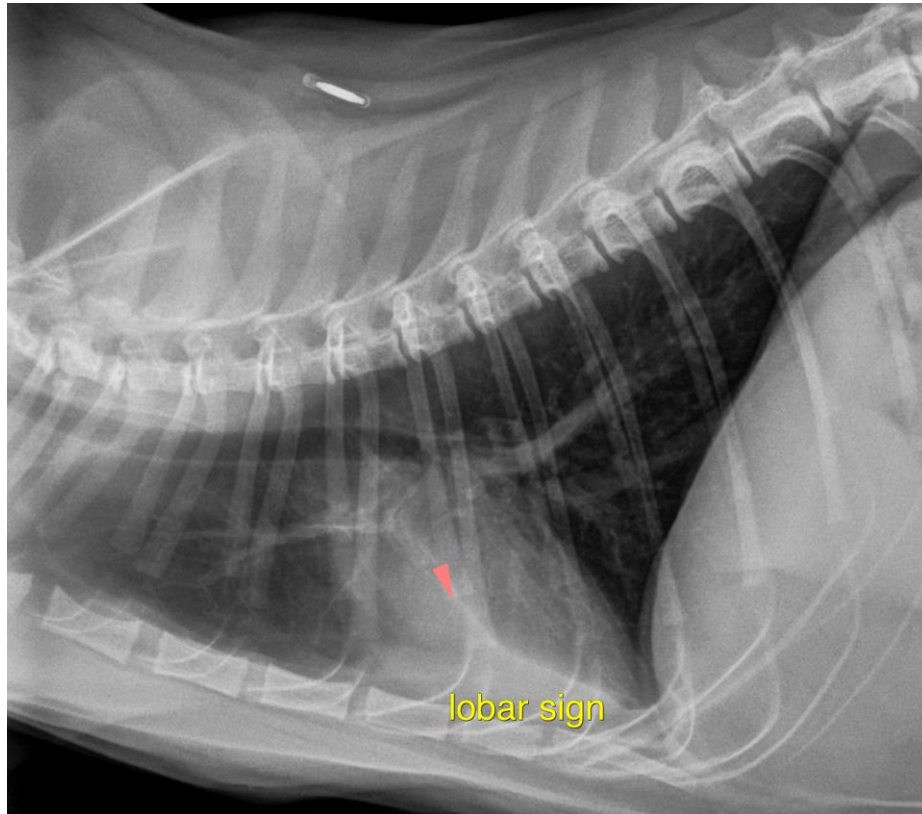
Taylor Morrison

**INVOICE**

50415

**DATE**

2-19-22



The information and recommendations provided are based on the images presented by the referring veterinarian/sonographer. No evaluation can be communicated regarding pathology that was not visible in the image/video clips provided.

Thank you for this referral. If the clinical or image interpretation does not parallel your findings or if I can be of any further assistance please contact me.

**Nele Eley**, DVM, Dr. med. vet., DipECVDI  
European Specialist in Veterinary Diagnostic Imaging, Cert. Radiology,  
Senior lecturer University of Giessen, Germany, Veterinary Faculty, Department of Radiology  
Nele.Eley@sonopath.com