



**PATIENT**

Bear Mitchell

**PRESENTING CLINICAL SIGNS**

Limping on the right front leg  
 Abnormal PE/Chem/CBC/UA Results: PE: 2/5 RIGHT FRONT LAME AT WALK AND TROT. NO HEAT, SWELLING, PAIN, INFLAMMATION OR NECK PAIN DETECTED. NOT ANY MORE LAME AFTER MANIPULATION THAN BEFORE. NO RECENT LABS

**SPECIES**

Canine

**RADIOGRAPHIC STUDY OF THE FRONT LIMBS**

From the shoulders to the paws - mediolateral and craniocaudal views of both elbows, both front paws, and mediolateral views of both shoulders totaling 12 images available for review.

**BREED**

Rottweiler Mix

**RADIOGRAPHIC FINDINGS**

**Shoulders**

Mild regional increase in opacity is noted level with the intertubercular groove of the biceps tendon in both shoulders. The subchondral bones of the glenoid cavities and humeral heads present intact and smooth. No evidence of osteoarthritic changes is seen.

**SEX**

Neutered Male

**Elbows**

Mild contour blurring and decrease in opacity is seen in the medial coronoid processes in both elbows. The joint spaces are congruent. No evidence of subchondral bone defects is noted.

**AGE**

6 Years, 11 Months

A minimal osteophyte is present on the proximal contour of the anconeal process in both elbows.

**INTERPRETED BY**

Nele Eley, DVM  
 Dr. med. Vet. DipECVDI

**Front Paws**

Both carpal joints and metacarpophalangeal joints present within normal limits.

**HOSPITAL NAME**

Elizabeth Animal Hospital

**RADIOGRAPHIC DIAGNOSIS**

- Mild exostosis within the intertubercular groove of the biceps tendon in both shoulders.
- Minimal elbow osteoarthritis in both front limbs.

**REFERRING VET**

Leon Anderson, DVM

**INTERPRETATION OF THE FINDINGS & FURTHER RECOMMENDATIONS**

The radiographic study reveals potential for an osseous exostosis within the intertubercular groove of the biceps tendon in both shoulders. The radiographic changes are mild. Moreover, minimal signs of elbow osteoarthritis are present in both elbows. All noted changes are mild and bilaterally symmetric. Their clinical significance is questionable; however, I cannot rule out presence of biceps tenosynovitis nor of medial coronoid pathology even though, especially in rottweilers with these very mild arthritic changes, clinical significance is very rare.

**INVOICE**

50421

**DATE**

2-19-22



**PATIENT**

Bear Mitchell

**SPECIES**

Canine

**BREED**

Rottweiler Mix

**SEX**

Neutered Male

**AGE**

6 Years, 11 Months

**INTERPRETED BY**

Nele Eley, DVM  
Dr. med. Vet. DipECVDI

**HOSPITAL NAME**

Elizabeth Animal  
Hospital

**REFERRING VET**

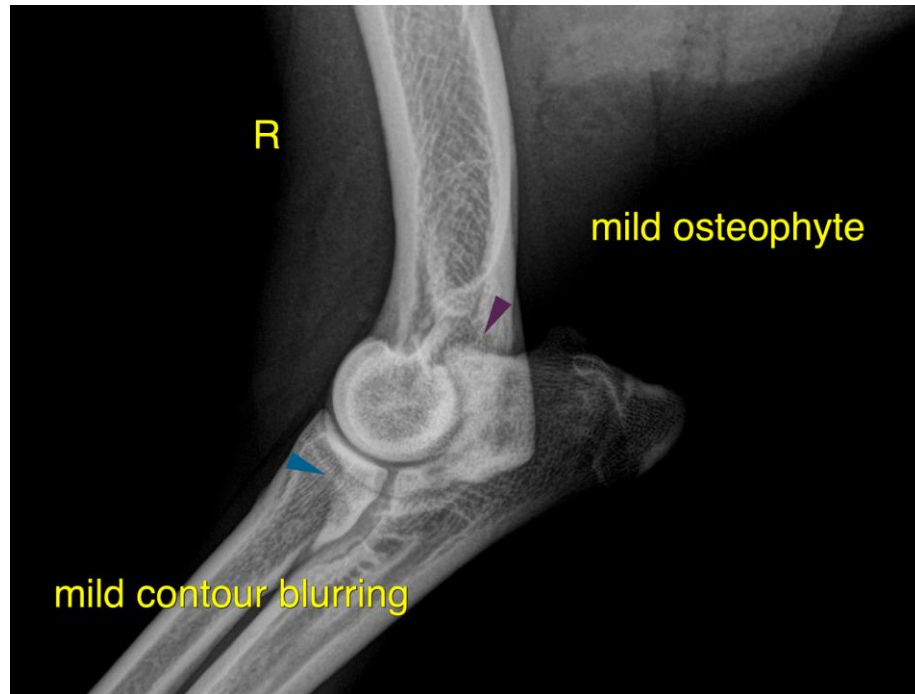
Leon Anderson, DVM

**INVOICE**

50421

**DATE**

2-19-22



The information and recommendations provided are based on the images presented by the referring veterinarian/sonographer. No evaluation can be communicated regarding pathology that was not visible in the image/video clips provided.

Thank you for this referral. If the clinical or image interpretation does not parallel your findings or if I can be of any further assistance please contact me.

**Nele Eley**, DVM, Dr. med. vet., DipECVDI  
European Specialist in Veterinary Diagnostic Imaging, Cert. Radiology,  
Senior lecturer University of Giessen, Germany, Veterinary Faculty, Department of Radiology  
Nele.Eley@sonopath.com