



PATIENT PRESENTING CLINICAL SIGNS

- Wally Rowe
- Presented a month ago for suspect IVDD; got laser, crating and pain management and got better. Came in acutely lame RH
 - Gav PRP bilaterally today

SPECIES

Canine

ULTRASONOGRAPHIC STUDY OF THE BILATERAL STIFLES

ULTRASONOGRAPHIC FINDINGS

BREED

Doodle

RIGHT

Mild anechoic effusion and synovial thickening of the supra and infrapatellar recesses are noted. There is mild osteophytosis along femoral condyles and tibial plateau.

SEX

MN

The cranial cruciate ligament presents ruptured echogenic fibers at the distal attachment at the intercondylar eminence of the tibia.

The medial and lateral menisci are normal in position, signal and structure.

AGE

7yr

LEFT

Minimal anechoic effusion is noted with early periarticular bone remodeling.

INTERPRETED BY

Nele Eley (Ondreka),
DVM Dr. med. vet.,
DipECVDI

The cranial cruciate ligament is continuous and smoothly delineated.

The lateral and medial meniscus are normal in signal, position, and structure.

ULTRASONOGRAPHIC DIAGNOSIS

- Cranial cruciate injury in the right stifle joint
- Normal ultrasonographic presentation of the left cranial cruciate ligament
- Normal ultrasonographic presentation of bilateral menisci

HOSPITAL NAME

Mill Brook Animal
Clinic

INTERPRETATION OF FINDINGS & FURTHER RECOMMENDATIONS

The ultrasonographic study reveals evidence of mild degenerative joint disease and cranial cruciate ligament injury in the right stifle joint. The menisci are intact which is favorable for prognosis and potential surgical stabilization.

REFERRING VET

Michele Pfannenstiel

The left stifle is unremarkable except for mild effusion at this point with no evidence of cranial cruciate ligament injury or meniscal injury.

INVOICE

23920

DATE

02/18/2026



PATIENT

Wally Rowe

SPECIES

Canine

BREED

Doodle

SEX

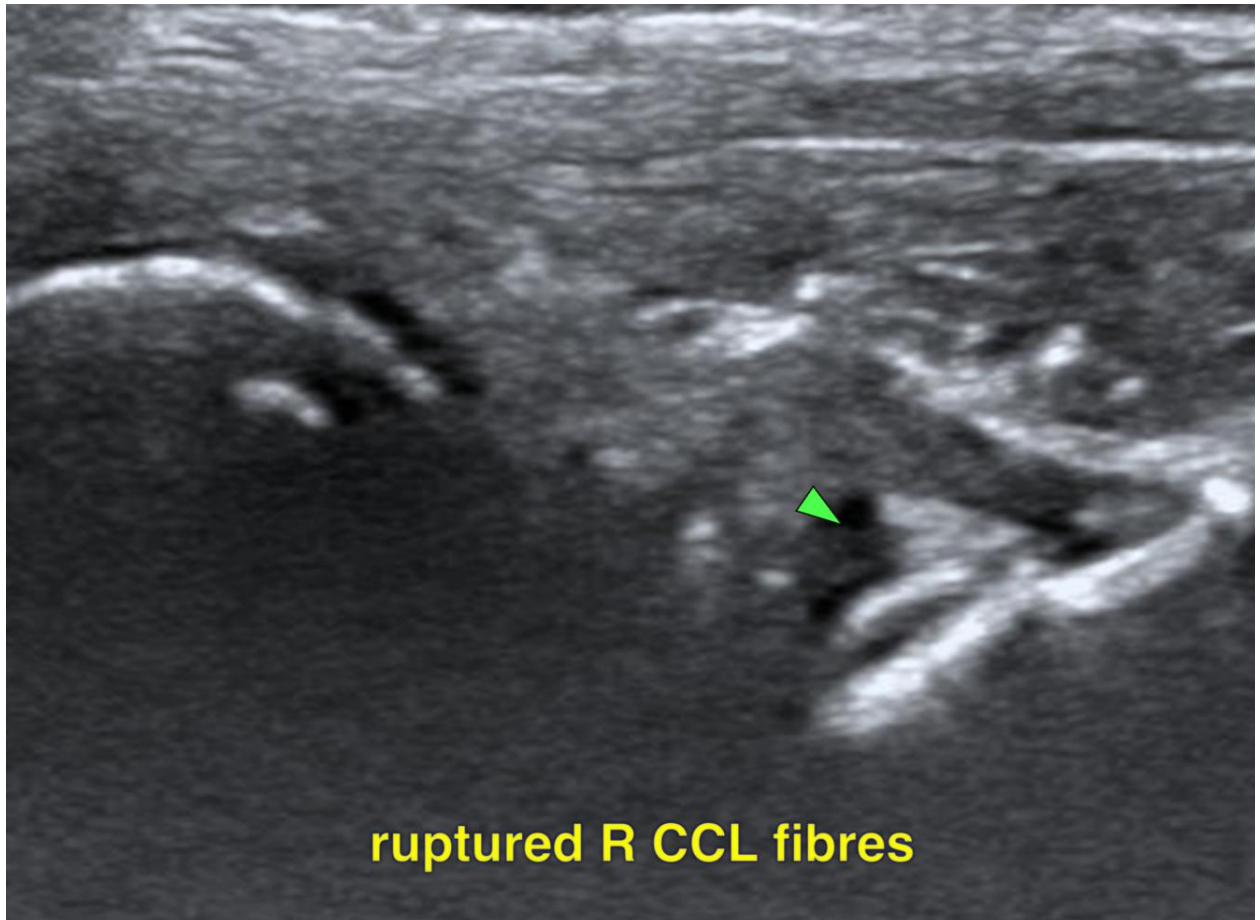
MN

AGE

7yr

INTERPRETED BY

Nele Eley (Ondreka),
DVM Dr. med. vet.,
DipECVDI



ruptured R CCL fibres

HOSPITAL NAME

Mill Brook Animal
Clinic

REFERRING VET

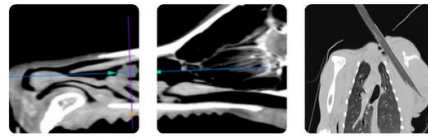
Michele Pfannenstiel

INVOICE

23920

DATE

02/18/2026



PATIENT

Wally Rowe

SPECIES

Canine

BREED

Doodle

SEX

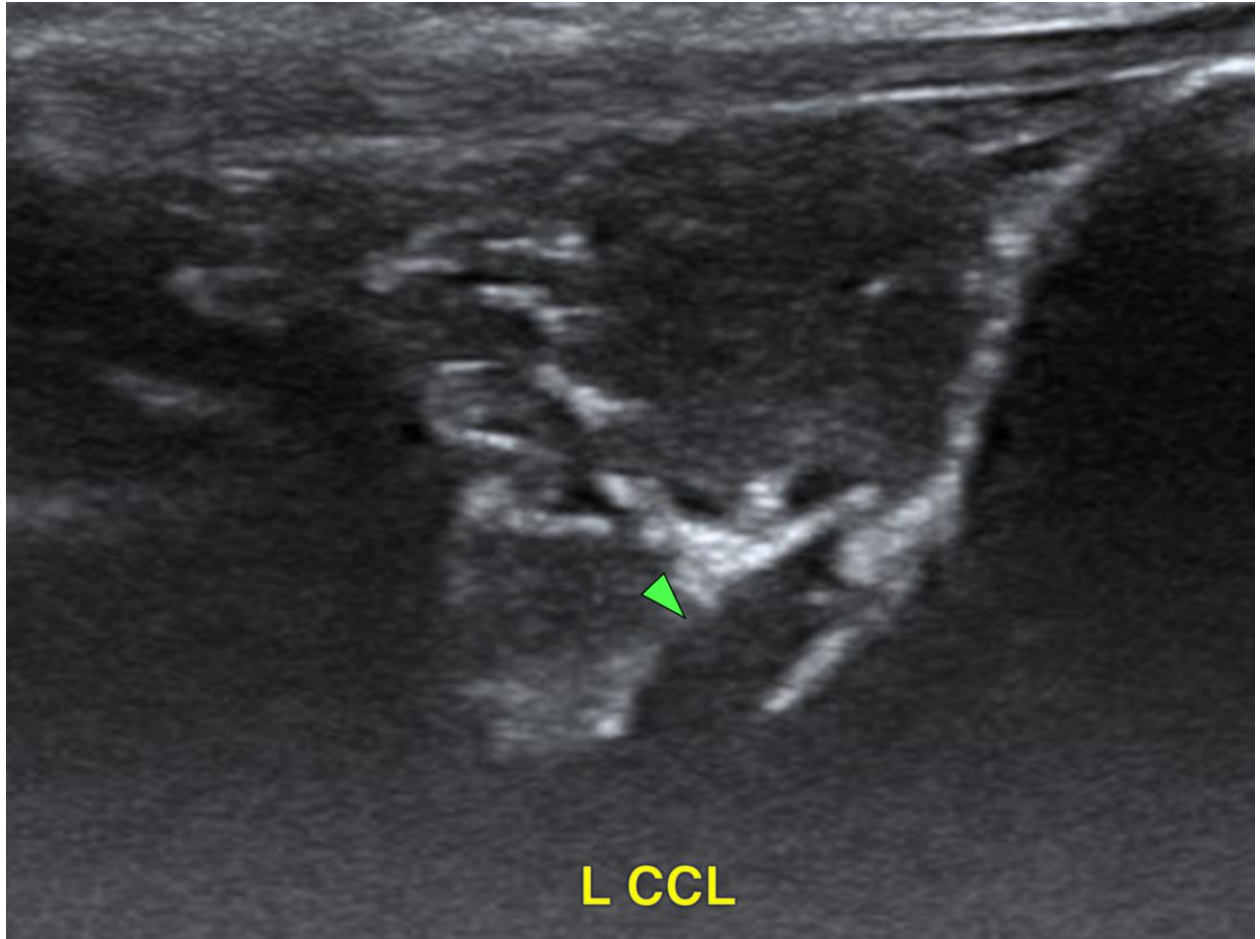
MN

AGE

7yr

INTERPRETED BY

Nele Eley (Ondreka),
DVM Dr. med. vet.,
DipECVDI



HOSPITAL NAME

Mill Brook Animal
Clinic

REFERRING VET

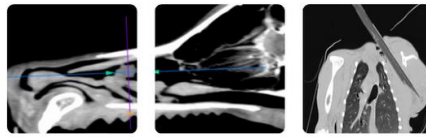
Michele Pfannenstiel

INVOICE

23920

DATE

02/18/2026



PATIENT

Wally Rowe

The information and recommendations provided are based on the images presented by the referring veterinarian. No evaluation can be communicated regarding pathology that was not visible in the image/video clips provided.

SPECIES

Canine

Thank you for this referral. If the clinical or image interpretation does not parallel your findings or if I can be of any further assistance please contact me.

BREED

Doodle

Nele Eley (Ondreka), DVM, Dr. med. vet., DipECVDI
European Specialist in Veterinary Diagnostic Imaging, Cert. Radiology,
Senior lecturer University of Giessen/Germany, Veterinary Faculty, Department of Radiology.
info@sonopath.com

SEX

MN

AGE

7yr

INTERPRETED BY

Nele Eley (Ondreka),
DVM Dr. med. vet.,
DipECVDI

HOSPITAL NAME

Mill Brook Animal
Clinic

REFERRING VET

Michele Pfannenstiel

INVOICE

23920

DATE

02/18/2026