



PATIENT PRESENTING CLINICAL SIGNS

Thor Walsh Thor has shown some general lameness/weakness over the last 12-18 months, originally seemed to improve with Adequan and Galliprant. Suspected osteoarthritis. Rads taken showed no/little OA and exam showed some weakness and hind limb loss of CP

SPECIES Overall neuro is normal.

Canine COMPUTED TOMOGRAPHIC STUDY OF THE LUMBAR SPINE

CT study of the lumbar spine, plain and myelogram of the lumbar spine available for review.

BREED COMPUTED TOMOGRAPHIC FINDINGS

Pitbull Mix The number, general alignment and anatomy of the lumbar vertebrae are within normal limits.

SEX The lumbosacral intervertebral disc shows mild protrusion with no evidence of cauda equina compression.

MN The subarachnoid space is normal with no deviation, compression or widening detected.

AGE Mild degenerative changes are seen at the lumbosacral junction with mild spondylosis and at L1-2 with moderate spondylosis and spondylarthrosis.

11yr Mild bilateral osteoarthritis of the coxofemoral joints is seen.

INTERPRETED BY There is no evidence of myelopathy, spinal canal stenosis or other spinal abnormality.

Nele Eley (Ondreka),
DVM Dr. med. vet.,
DipECVDI

COMPUTED TOMOGRAPHIC DIAGNOSIS

- Mild lumbosacral disc protrusion
- Spondylosis at L1-2 and lumbosacral junction
- Mild bilateral hip osteoarthritis

HOSPITAL NAME

Green Prairie Animal
Hospital

INTERPRETATION OF FINDINGS & FURTHER RECOMMENDATIONS

The imaging findings correlate with age related degenerative changes. There is no evidence of compressive myelopathy or significant neurologic compromise.

REFERRING VET The lumbosacral disc protrusion does not appear to be compressive currently and is unlikely to be the sole cause of significant hind limb malfunction.

Dr. Bri McLaughlin

The mild hip osteoarthritis may contribute to mild lameness and reduced range of motion.

INVOICE The negative findings may support the presence of degenerative or other myelopathy. Repeat imaging such as MRI could be considered if neurological signs worsen.

23919

DATE

02/18/2026



PATIENT

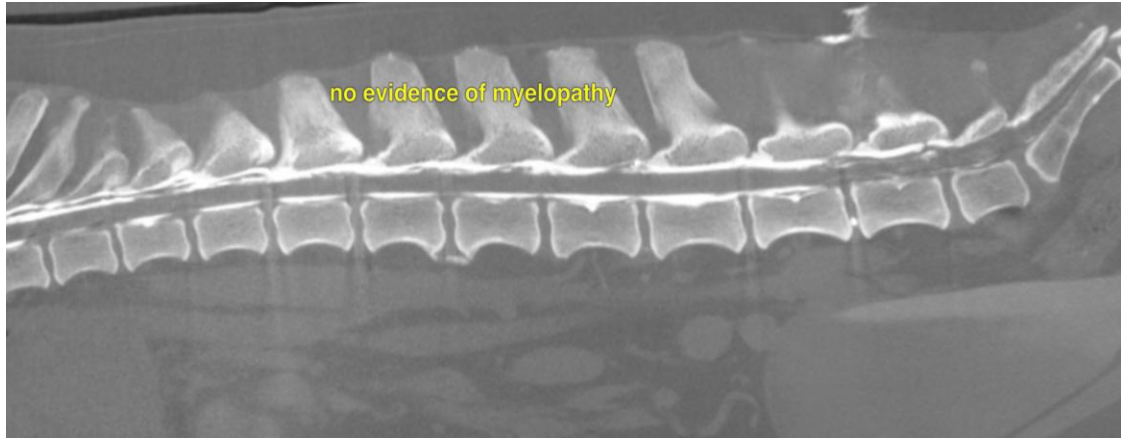
Thor Walsh

SPECIES

Canine

BREED

Pitbull Mix



SEX

MN

The information and recommendations provided are based on the images presented by the referring veterinarian. No evaluation can be communicated regarding pathology that was not visible in the image/video clips provided.

AGE

11yr

Thank you for this referral. If the clinical or image interpretation does not parallel your findings or if I can be of any further assistance please contact me.

INTERPRETED BY

Nele Eley (Ondreka),
DVM Dr. med. vet.,
DipECVDI

Nele Eley (Ondreka), DVM, Dr. med. vet., DipECVDI
European Specialist in Veterinary Diagnostic Imaging, Cert. Radiology,
Senior lecturer University of Giessen/Germany, Veterinary Faculty, Department of Radiology.
info@sonopath.com

HOSPITAL NAME

Green Prairie Animal
Hospital

REFERRING VET

Dr. Bri McLaughlin

INVOICE

23919

DATE

02/18/2026