



PATIENT

River Strempel

SPECIES

Feline

BREED

DSH

SEX

MN

AGE

1Y, 9M

WEIGHT

10.9lbs

INTERPRETED BY

Nele Eley (Ondreka),
DVM Dr. med. vet.,
DipECVDI

IMAGING PERFORMED BY

Tracy Eure

HOSPITAL NAME

Moyock Animal
Hospital

REFERRING VET

Tracy Eure

INVOICE

73847

DATE

2-18-26

PRESENTING CLINICAL SIGNS

- owner reports abnormal gait x1year; improved on meloxicam

Abnormal PE/Chem/CBC/UA Results: none

RADIOGRAPHIC STUDY OF THE STIFLES

Mediolateral and craniocaudal views of both stifles available for review in jpg format.

RADIOGRAPHIC FINDINGS

Both stifles present normal joint alignment and congruity. Patellae are appropriately positioned within the trochlear grooves bilaterally with no evidence of luxation. No periarticular osteophyte formation. No evidence of trauma. No subchondral bone sclerosis, lysis, or articular surface irregularity is identified. There is no evidence of articular enlargement or capsular distension. No radiographic evidence of cranial tibial subluxation is noted.

Subjective reduction in muscle mass of the left pelvic limb is present suggesting disuse atrophy.

RADIOGRAPHIC DIAGNOSIS

- Radiographically normal bilateral stifles.
- Left pelvic limb muscle atrophy consistent with chronic disuse or neurologic dysfunction rather than primary stifle pathology.

INTERPRETATION OF FINDINGS & FURTHER RECOMMENDATIONS

There is no radiographic evidence of orthopedic disease affecting the stifles to explain the chronic gait abnormality.

The unilateral muscle atrophy suggests that the lameness is more likely a consequence of orthopedic condition further proximal or distal in the left hind limb or neurologic etiology. Further evaluation of the hips and lumbosacral spine could be considered by means of radiographs or advanced imaging. Neurologic assessment should be considered if not already performed.



PATIENT

River Stempel

SPECIES

Feline

BREED

DSH

SEX

MN

AGE

1Y, 9M

WEIGHT

10.9lbs

INTERPRETED BY

Nele Eley (Ondreka),
DVM Dr. med. vet.,
DipECVDI

IMAGING PERFORMED BY

Tracy Eure

HOSPITAL NAME

Moyock Animal
Hospital

REFERRING VET

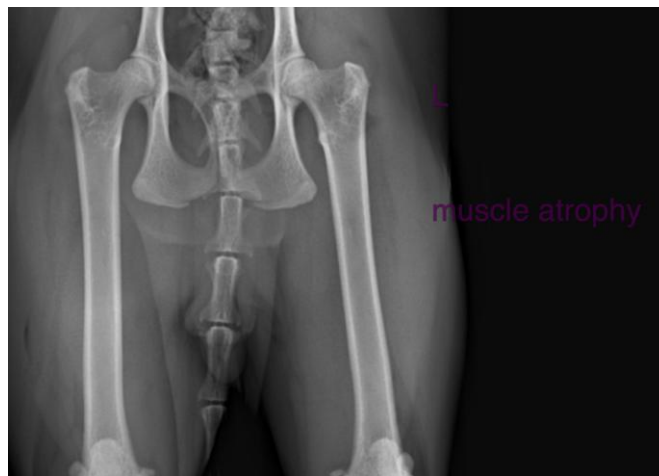
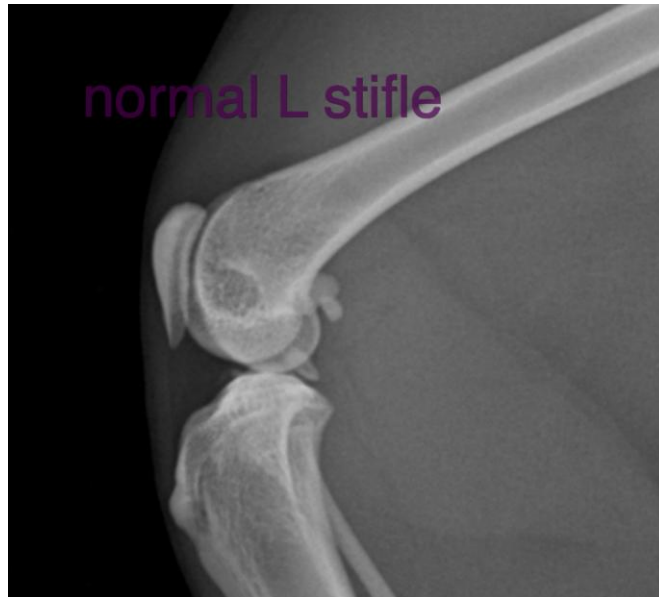Tracy Eure

INVOICE

73847

DATE

2-18-26



The information and recommendations provided are based on the images presented by the referring veterinarian. No evaluation can be communicated regarding pathology that was not visible in the image/video clips provided.

Thank you for this referral. If the clinical or image interpretation does not parallel your findings or if I can be of any further assistance please contact me.

Nele Eley (Ondreka), DVM, Dr. med. vet., DipECVDI
European Specialist in Veterinary Diagnostic Imaging, Cert. Radiology,
Senior lecturer University of Giessen/Germany, Veterinary Faculty, Department of Radiology.
info@sonopath.com