



**PATIENT**

Daisy Nendel

**PRESENTING CLINICAL SIGNS**

Pet has been tiring more easy on walks and is panting more than normal. Also seems painful and cries when O is picking her up.

**SPECIES**

Canine

Abnormal PE/Chem/CBC/UA Results: Elevated BUN 29.1 (9.0-29), HCT 57.5 (33-56). Rest normal including creatinine 0.8 (0.4 - 1.4). Palpation along spine - flinch at TL junction but not repeatable. Grade II-III Heart murmur, left systolic - NEW FINDING

**BREED**

Papillon Mix

**RADIOGRAPHIC STUDY OF THE THORAX**

Right lateral and ventrodorsal views totaling 2 images available for review.

**RADIOGRAPHIC FINDINGS**

The radiographic presentation of the thoracolumbar spine is within age related normal limits.

**SEX**

FS

The vertebral heart score is 11. No overt left atrial enlargement is seen. There is no evidence of pulmonary venous congestion and no evidence of cardiogenic pulmonary edema. The trachea does not appear to be elevated.

**AGE**

8 Years, 3 Months

Course and width of the trachea are considered within normal limits. No evidence of mediastinal widening is seen.

The degree of pulmonary inflation is moderate. A mild generalized bronchointerstitial lung pattern which is considered within age related normal limits is seen.

**INTERPRETED BY**

Nele Eley, DVM  
Dr. med. Vet. DipECVDI

There is mild generalized enlargement of the liver with pointed liver margins.

A mild amount of gravel is seen within the stomach.

**HOSPITAL NAME**

Grove Veterinary  
Clinic

**RADIOGRAPHIC DIAGNOSIS**

- Mild unspecific cardiomegaly.
- No radiographic evidence of left atrial enlargement or congestive heart failure.

**REFERRING VET**

Dr. Lynne Luna

**INTERPRETATION OF THE FINDINGS & FURTHER RECOMMENDATIONS**

The shape of the cardiac silhouette is within the expected limits. There is no evidence of specific chamber enlargement and no evidence of congestive heart failure. The left atrium does not appear to be enlarged at this point. The patient may benefit from a full cardiac echo since a valvular insufficiency secondary to endocardiosis is suspected.

**INVOICE**

50412

**DATE**

2-18-22



**PATIENT**

Daisy Nendel

**SPECIES**

Canine

**BREED**

Papillon Mix

**SEX**

FS

**AGE**

8 Years, 3 Months

**INTERPRETED BY**

Nele Eley, DVM  
Dr. med. Vet. DipECVDI

**HOSPITAL NAME**

Grove Veterinary  
Clinic

**REFERRING VET**

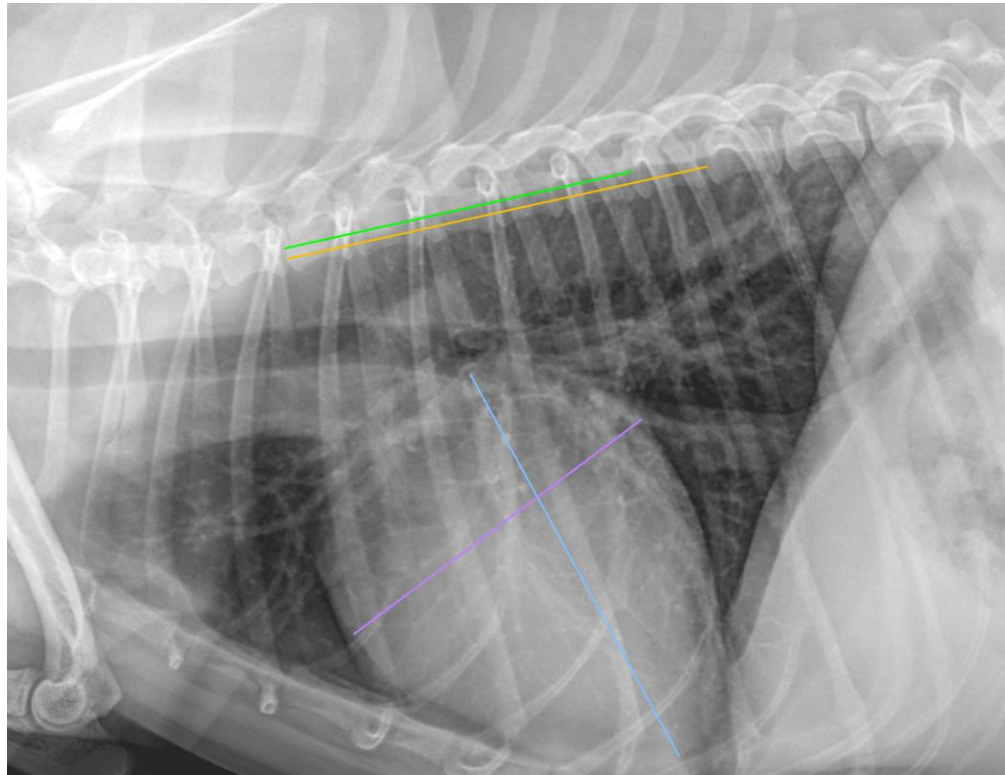
Dr. Lynne Luna

**INVOICE**

50412

**DATE**

2-18-22



**The information and recommendations provided are based on the images presented by the referring veterinarian/sonographer. No evaluation can be communicated regarding pathology that was not visible in the image/video clips provided.**

Thank you for this referral. If the clinical or image interpretation does not parallel your findings or if I can be of any further assistance please contact me.

**Nele Eley**, DVM, Dr. med. vet., DipECVDI  
European Specialist in Veterinary Diagnostic Imaging, Cert. Radiology,  
Senior lecturer University of Giessen, Germany, Veterinary Faculty, Department of Radiology  
Nele.Eley@sonopath.com