SonoPath Teleradiology

EDUCATIONAL TELECONSULTATION SERVICES™

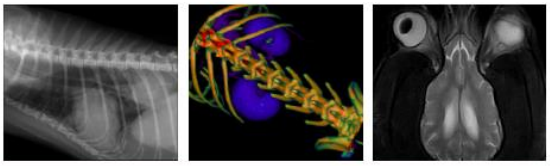

SonoPath.com
1-800-838-4268 info@sonopath.com

PATIENT

Addison Hunter

SPECIES

Canine

BREED

Lab Retriever Mix

SEX

Hunter

AGE

13 Years, 11 Months

INTERPRETED BY

Nele Eley, DVM
Dr. med. Vet. DipECVDI

HOSPITAL NAME

Ahwatukee Commons Veterinary Hospital

REFERRING VET

Linda R. Elliott, D.V.M

INVOICE

50506

DATE

2-18-22

PRESENTING CLINICAL SIGNS

Pt presents with diarrhea going on for the past 3-4 days. Some lethargy, decreased eating and increased drinking began Monday/Tuesday this week. Owner states that Pt has been straining to have a bowel movement, Owner attributes it to decrease in eating. Owner also states that diarrhea has a liquid consistency, orange in color, no blood or mucous noticed. Pt has been exhibiting abdominal breathing and a hoarse superficial cough. Desert blood profile, urinalysis, and fecal - all sent, pending results.

RADIOGRAPHIC STUDY OF THE THORAX & ABDOMEN

Right/left lateral and ventrodorsal views of the thorax and lateral and ventrodorsal views of the abdomen totaling 7 images available for review.

RADIOGRAPHIC FINDINGS

Thorax

Moderate ventrally bridging spondyloses are seen between T3 and T4, and T5 and T6.

The degree of pulmonary inflation is fair.

The large abdominal volume appears to reduce the thoracic volume.

There is a lobar alveolar sign with maintained pulmonary volume affecting the right middle lobe. The remainder of the lung presents a mild bronchointerstitial increase in opacity with regular distribution.

No evidence of mediastinal widening is seen.

There is no radiographic evidence of cardiovascular pathology.

Course and width of the trachea present within normal limits.

Abdomen

The patient is obese.

Generalized osteopenia is noted.

Severe ventrally bridging spondylosis is present between L3 and L4.

The abdominal volume appears to be large.

The urinary bladder and kidneys present within the expected limits.

The stomach contains a moderate amount of ingesta and gas.

The small intestinal loops are turgid in appearance with predominance of a gas pattern. No evidence of abnormal dilation, plication, or radiopaque foreign material is seen.

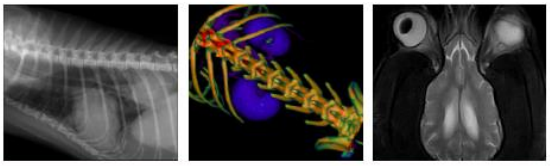

SonoPath.com
1-800-838-4268 info@sonopath.com

PATIENT

Addison Hunter

SPECIES

Canine

BREED

Lab Retriever Mix

SEX

Hunter

AGE

13 Years, 11 Months

INTERPRETED BY

Nele Eley, DVM
Dr. med. Vet. DipECVDI

HOSPITAL NAME

Ahwatukee Commons Veterinary Hospital

REFERRING VET

Linda R. Elliott, D.V.M

INVOICE

50506

DATE

2-18-22

The colon and cecum contain a mild amount of fecal material.

RADIOGRAPHIC DIAGNOSIS

- Lobar alveolar sign of the right middle lobe.
- Gastrointestinal maldigestion pattern.
- Osteopenia.
- Obesity.
- Spondyloses.

INTERPRETATION OF THE FINDINGS & FURTHER RECOMMENDATIONS

Differential diagnosis for the lobar alveolar sign includes lobar pneumonia, lobar neoplasia, and less likely lobar hemorrhage. Atelectasis does not seem to be an applicable differential diagnosis in this case owing to the preserved pulmonary volume. Consider recheck radiographs and ultrasound guided fine needle aspiration using a right parasternal intercostal approach for further definition should the radiographic findings be stationary.

The radiographic study of the abdomen reveals a maldigestion pattern. No evidence of mechanical ileus is seen. The findings parallel the history of diarrhea.

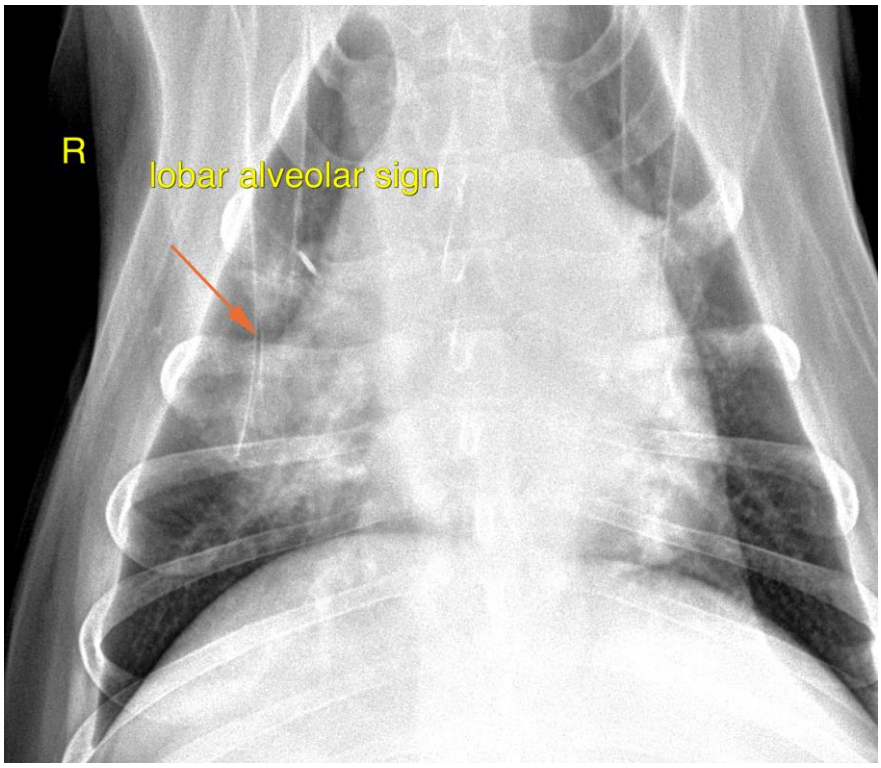

SonoPath Teleradiology

EDUCATIONAL TELECONSULTATION SERVICES™

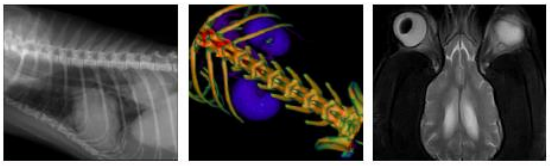

SonoPath.com
1-800-838-4268 info@sonopath.com

PATIENT

Addison Hunter

SPECIES

Canine

BREED

Lab Retriever Mix

SEX

Hunter

AGE

13 Years, 11 Months

INTERPRETED BY

Nele Eley, DVM
Dr. med. Vet. DipECVDI

HOSPITAL NAME

Ahwatukee Commons
Veterinary Hospital

REFERRING VET

Linda R. Elliott, D.V.M

INVOICE

50506

DATE

2-18-22

The information and recommendations provided are based on the images presented by the referring veterinarian/sonographer. No evaluation can be communicated regarding pathology that was not visible in the image/video clips provided.

Thank you for this referral. If the clinical or image interpretation does not parallel your findings or if I can be of any further assistance please contact me.

Nele Eley, DVM, Dr. med. vet., DipECVDI
European Specialist in Veterinary Diagnostic Imaging, Cert. Radiology,
Senior lecturer University of Giessen, Germany, Veterinary Faculty, Department of Radiology
Nele.Eley@sonopath.com