



## PATIENT

Gunner Burgess

## SPECIES

Canine

## BREED

Labrador Retriever

## SEX

Male

## AGE

10Y

## WEIGHT

104lbs

## INTERPRETED BY

Nele Eley (Ondreka),  
DVM Dr. med. vet.,  
DipECVDI

## IMAGING PERFORMED BY

Tina Lynn, CVT/George  
Eales, DVM

## HOSPITAL NAME

Green Prairie Animal  
Hospital

## REFERRING VET

Laketown A.H. Dr.  
Felgenhauer

## INVOICE

73795

## DATE

2-17-26

## PRESENTING CLINICAL SIGNS

- History of urine per referring veterinarian
- O did report that they thought possible a mass in penis but not noted on referral form
- Treated with Augmentin and Ostimax w/out resolution
- Is intact

## COMPUTED TOMOGRAPHIC STUDY OF THE ABDOMEN

Abdominal CT with IV contrast and retrograde urethrogram available for review.

## COMPUTED TOMOGRAPHIC FINDINGS

The prostate presents moderate symmetric enlargement measuring 5.8 x 4.4 x 5.0 cm with normal shape and attenuation for an intact adult male. No focal lesions, cysts, or mineralizations are noted.

The urinary bladder is normal in size and wall thickness. The ureteral papillae positions are within normal limits. The cystourethral junction presents within normal limits. Retrograde urethrogram demonstrates patent urethra with no filling defects. No evidence of intraluminal mass or obstruction is seen.

The testicles appear normal in size, position, and attenuation. No focal penile mass can be identified on CT (with the limitation of oversaturation of superficial soft tissues).

Both kidneys present within normal limits for size, shape and organ architecture. After contrast administration, a bilaterally symmetric and uniform nephro- and pyelogram is noted.

The adrenal glands are within normal limits for size, shape and organ architecture.

Both liver and spleen present with normal shape, even surface, uniformly attenuating parenchyma and homogeneous contrast enhancement, unremarkable.

The pancreas is evenly contoured; the pancreatic parenchyma is homogeneous and presents uniform contrast enhancement.

The position, delineation, wall and content of the gastrointestinal tract are considered within normal limits throughout.

No evidence of intraabdominal masses, free fluid, or abnormal lymphadenopathy is detected.

A large subcutaneous lipoma is present in the right body wall.

Moderate degenerative lumbosacral stenosis is noted.

## COMPUTED TOMOGRAPHIC DIAGNOSIS

- No evidence of abdominal prostatic, urethral, or penile mass.
- Patent urinary tract on retrograde urethrogram.
- Body wall lipoma.
- Degenerative lumbosacral stenosis.

## INTERPRETATION OF FINDINGS & FURTHER RECOMMENDATIONS

The abdominal and urogenital CT shows no mass or obstructive lesion including prostate, urethra, and



## PATIENT

Gunner Burgess

## SPECIES

Canine

## BREED

Labrador Retriever

## SEX

Male

## AGE

10Y

## WEIGHT

104lbs

## INTERPRETED BY

Nele Eley (Ondreka),  
DVM Dr. med. vet.,  
DipECVDI

## IMAGING PERFORMED BY

Tina Lynn, CVT/George  
Eales, DVM

## HOSPITAL NAME

Green Prairie Animal  
Hospital

## REFERRING VET

Laketown A.H. Dr.  
Felgenhauer

## INVOICE

73795

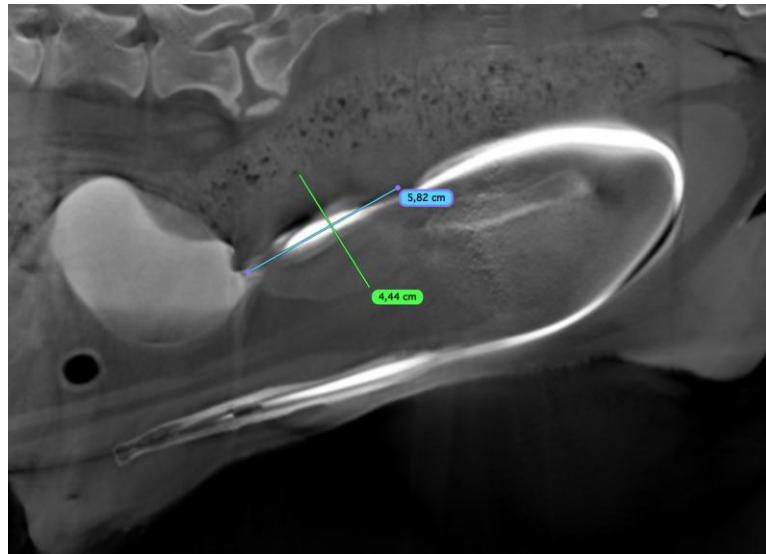
## DATE

2-17-26

penis.

Degenerative lumbosacral stenosis is present.

The clinical urinary signs are likely nonneoplastic. Consider urinalysis and urine culture to rule out infection if not performed already. Ultrasound may be added to evaluate for subtle urethral or bladder wall changes with greater sensitivity. Referral to a urologist if clinical signs persist despite medical management could be considered.



The information and recommendations provided are based on the images presented by the referring veterinarian. No evaluation can be communicated regarding pathology that was not visible in the image/video clips provided.

Thank you for this referral. If the clinical or image interpretation does not parallel your findings or if I can be of any further assistance please contact me.

**Nele Eley (Ondreka)**, DVM, Dr. med. vet., DipECVDI  
European Specialist in Veterinary Diagnostic Imaging, Cert. Radiology,  
Senior lecturer University of Giessen/Germany, Veterinary Faculty, Department of Radiology.  
[info@sonopath.com](mailto:info@sonopath.com)