



PATIENT

Banzai Verrasto

SPECIES

Canine

BREED

Terrier Mix

SEX

FS

AGE

12Y, 8M

WEIGHT

45

INTERPRETED BY

Nele Eley (Ondreka),
DVM Dr. med. vet.,
DipECVDI

IMAGING PERFORMED BY

Cathy Bond

HOSPITAL NAME

Pocono Peak
Veterinary Center

REFERRING VET

Dr. Christine Coyle

INVOICE

73790

DATE

2-17-26

PRESENTING CLINICAL SIGNS

Presented for coughing and panting.

RADIOGRAPHIC STUDY OF THE THORAX

Right/left lateral and ventrodorsal views of the thorax totaling 3 images available for review.

RADIOGRAPHIC FINDINGS

A solitary soft tissue opaque pulmonary mass is present within the right caudal lung lobe, ovoid in appearance, and measuring approximately 3.6 cm in diameter. No additional pulmonary nodules or masses are identified. The remaining pulmonary parenchyma shows mild age related bronchial markings without evidence of a diffuse interstitial or alveolar pattern.

The cardiac silhouette is normal in size and shape with VHS of 10.

The trachea is normal in position and diameter.

The mediastinum and pleural space appear unremarkable.

RADIOGRAPHIC DIAGNOSIS

- Solitary pulmonary mass in the right caudal lung lobe.
- No additional nodules.
- Otherwise, normal age related lung.
- No radiographic evidence of cardiogenic disease.

INTERPRETATION OF FINDINGS & FURTHER RECOMMENDATIONS

The radiographic study reveals a pulmonary soft tissue mass in the right caudal lung lobe. Primary differential considerations include primary pulmonary neoplasia such as bronchial carcinoma and less likely granuloma, abscess, or metastatic disease. Thoracic CT can be recommended for staging and better characterization of the mass. Tissue sampling would be ideal for a definitive diagnosis, however, the mass is not accessible for ultrasound guided sampling. CT guided sampling or lung lobectomy with histopathology could be considered for further definition in this patient.



PATIENT

Banzai Verrasto

SPECIES

Canine

BREED

Terrier Mix

SEX

FS

AGE

12Y, 8M

WEIGHT

45

INTERPRETED BY

Nele Eley (Ondreka),
DVM Dr. med. vet.,
DipECVDI

IMAGING PERFORMED BY

Cathy Bond

HOSPITAL NAME

Pocono Peak
Veterinary Center

REFERRING VET

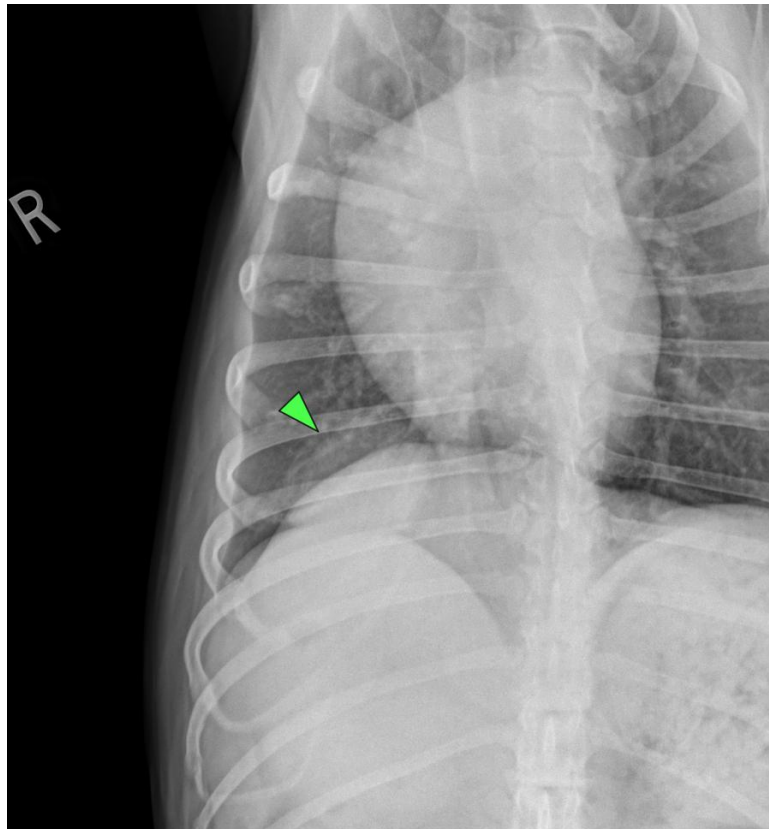
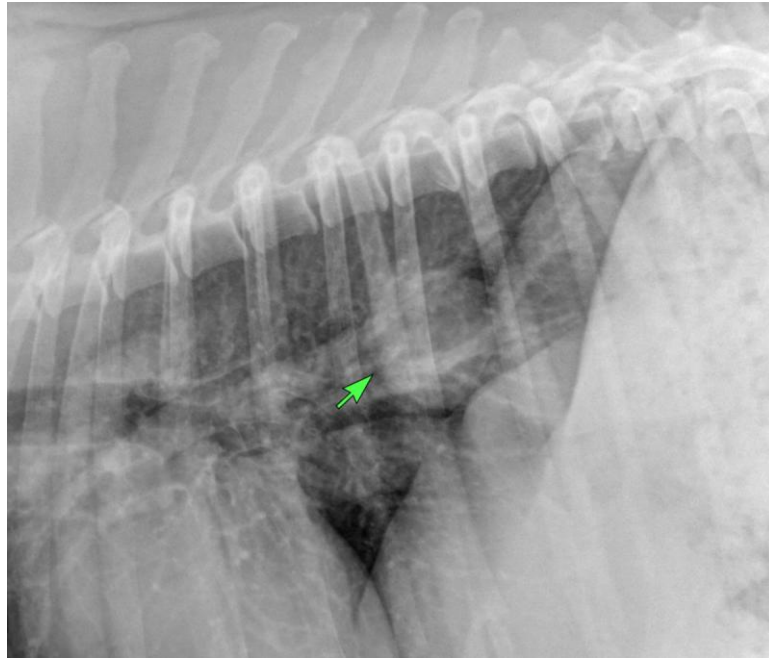
Dr. Christine Coyle

INVOICE

73790

DATE

2-17-26





PATIENT

Banzai Verrasto

SPECIES

Canine

BREED

Terrier Mix

SEX

FS

AGE

12Y, 8M

WEIGHT

45

INTERPRETED BY

Nele Eley (Ondreka),
DVM Dr. med. vet.,
DipECVDI

IMAGING PERFORMED BY

Cathy Bond

HOSPITAL NAME

Pocono Peak
Veterinary Center

REFERRING VET

Dr. Christine Coyle

INVOICE

73790

DATE

2-17-26

The information and recommendations provided are based on the images presented by the referring veterinarian. No evaluation can be communicated regarding pathology that was not visible in the image/video clips provided.

Thank you for this referral. If the clinical or image interpretation does not parallel your findings or if I can be of any further assistance please contact me.

Nele Eley (Ondreka), DVM, Dr. med. vet., DipECVDI

European Specialist in Veterinary Diagnostic Imaging, Cert. Radiology,

Senior lecturer University of Giessen/Germany, Veterinary Faculty, Department of Radiology.

info@sonopath.com